

# Persistent Subacute Thyroiditis Post SARS-CoV-2 Vaccine in a Male Patient with Positive Thyroid Autoantibodies

## Tiroid Otoantikörleri Pozitif Olan Erkek Hastada İnaktif SARS-CoV-2 Aşısından Sonra Gelişen Persistan Subakut Tiroidit

<sup>ID</sup> Ömercan TOPALOĞLU, <sup>ID</sup> Sakin TEKİN, <sup>ID</sup> Seda Nur TOPALOĞLU\*, <sup>ID</sup> Taner BAYRAKTAROĞLU

Division of Endocrinology and Metabolism, Zonguldak Bülent Ecevit University Faculty of Medicine, Zonguldak, TÜRKİYE

\*Department of Internal Medicine, Zonguldak Bülent Ecevit University Faculty of Medicine, Zonguldak, TÜRKİYE

### Abstract

Subacute thyroiditis (SAT) has been recently associated with severe acute respiratory syndrome-coronavirus-2 infection or vaccines against it. We report a case of a 41-year-old male patient who developed persistent SAT after the coronavirus disease-2019 (COVID-19) vaccination. He presented with sore throat and neck pain after the first dose of the COVID-19 vaccine (CoronaVac®). There was no history of a recent viral infection. Erythrocyte sedimentation rate (ESR) and C-reactive protein (CRP) were elevated, thyroid-stimulating hormone (TSH) and free thyroxine (fT4) were normal, COVID-19 polymerase chain reaction test was negative, and sonography showed thyroiditis in the right lobe. The symptoms resolved after treatment with methylprednisolone. However, 2 weeks after the second dose of the vaccine, the patient suffered from neck pain and hoarseness. TSH and fT4 were normal, but anti-thyroid peroxidase (anti-TPO), anti-thyroglobulin (anti-Tg), ESR, and CRP were elevated. Sonography revealed thyroiditis in the left lobe. The patient was treated with ibuprofen. On follow-up, hypothyroidism was diagnosed, and levothyroxine started. Hence, the clinicians should suspect the possibility of SAT in the vaccinated subjects.

**Keywords:** Subacute thyroiditis; COVID-19 vaccines; COVID-19

### Özet

Subakut tiroidit (SAT), son zamanlarda şiddetli akut solunum sendromu-koronavirüs-2 enfeksiyonu veya buna karşı geliştirilen aşılarla ilişkilendirilmektedir. Koronavirüs hastalığı-2019 [coronavirus disease-2019 (COVID-19)] aşılması sonrasında persistan SAT gelişen 41 yaşında erkek hastamızı sunuyoruz. COVID-19 aşısının (CoronaVac®) ilk dozundan sonra boğaz ağrısı ve boyun ağrısı ile başvurdu. Yakın zamanda viral enfeksiyon öyküsü yoktu. Eritrosit sedimentasyon hızı (ESH) ve C-reaktif protein (CRP) yükseldi, tiroid-stimüle edici hormon (TSH) ve serbest tiroksin (sT4) normaldi, COVID-19 polimeraz zincir reaksiyonu testi negatif ve sonografide sağ lobta tiroidit mevcuttu. Metilprednizolon tedavisi ile semptomlar geriledi. Ancak aşının 2. dozundan 2 hafta sonra hasta boyun ağrısı ve ses kısıklığından yakındı. TSH ve sT4 normaldi, anti-tiroid peroksidaz, anti-tiroglobülin, ESH ve CRP yükseldi. Sonografide sol lobta tiroidit izlendi. Hasta ibuprofen ile tedavi edildi. Takipte, hipotiroidizm tanısıyla levotiroksin başlandı. Dolayısıyla klinisyenler aşılanmış kişilerde SAT olasılığını akılda tutmalıdır.

**Anahtar kelimeler:** Subakut tiroidit; COVID-19 aşısı; COVID-19

### Introduction

Coronavirus disease-2019 (COVID-19), caused by severe acute respiratory syndrome-coronavirus-2 (SARS-CoV-2), was

declared a pandemic on March 11, 2020, and has affected more than 236 million people by October 2021 (1). SARS-CoV-2 infection may lead to multisystem involvement.

**Address for Correspondence:** Ömercan TOPALOĞLU, Division of Endocrinology and Metabolism, Zonguldak Bülent Ecevit University Faculty of Medicine, Zonguldak, TÜRKİYE  
**Phone:** +905059681817 **E-mail:** drhomeran@hotmail.com

Peer review under responsibility of Turkish Journal of Endocrinology and Metabolism.

**Received:** 11 Oct 2021 **Received in revised form:** 06 Dec 2021 **Accepted:** 14 Dec 2021 **Available online:** 29 Dec 2021

1308-9846 / © Copyright 2022 by Society of Endocrinology and Metabolism of Turkey.  
Publication and hosting by Türkiye Klinikleri.

This is an open access article under the CC BY-NC-SA license (<https://creativecommons.org/licenses/by-nc-sa/4.0/>)

Several reports suggest the possibility of association of COVID-19 with glycemic status (in diabetic and non-diabetic subjects) and obesity (2-6). Moreover, many other endocrine complications of SARS-CoV-2 infection, such as adrenal or sex hormone dysregulation or thyroid dysfunction, have been defined (2,7-9). Hashimoto's thyroiditis, Graves' disease, or subacute thyroiditis (SAT) have also been reported in patients after COVID-19 (9,10). High expression of angiotensin-converting enzyme 2 (ACE2) receptors in endocrine organs, including adrenal, pituitary, thyroid glands, and testes, may explain such complications (11-13).

SAT is characterized by neck pain which may radiate to the ears, jaw, upper neck, throat, or upper chest. It can result from post-viral inflammatory response associated with coxsackievirus, mumps, measles, adenovirus, as well as with SARS-CoV-2 infection (14,15). Most of the post-covid SAT cases occur  $\geq 14$  days after the onset of respiratory symptoms (15). The majority of these patients can be managed successfully with glucocorticoid therapy.

Apart from post-viral inflammation, SAT has also been associated with various antiviral vaccines such as influenza or hepatitis B vaccines (16-21). With mass vaccination programs running worldwide to reduce the mortality and morbidity in the COVID-19 pandemic, more than 5 billion doses of various types of COVID-19 vaccines have been administered (1). As a result, cases of SAT have also been reported after the COVID-19 vaccination (22-25).

We report a case of a patient who presented with persistent SAT, which developed after administration of inactivated COVID-19 vaccine (CoronaVac<sup>®</sup>, Sinovac Life Sciences, Beijing, Chinese).

### Case Report

A 41-year-old male was referred to the Zonguldak Atatürk State Hospital, Türkiye, with complaints of sore throat and neck pain for 1 week. There were no complaints of diarrhea, nausea, vomiting, palpitation, tremor, weight loss, or heat intolerance. His past medical history was remarkable for ulcerative colitis and asthma. He had a history of avascular necrosis of the hip, for which he underwent surgery 2 years ago. He had

been taking montelukast and mesalazine. The patient denied having a recent upper respiratory tract infection or pre-existing thyroid dysfunction. He had a history of COVID-19 infection eight months ago. He had a family history of Type 2 diabetes mellitus and hypertension. The patient has taken the first dose of the CoronaVac<sup>®</sup> vaccine 1 week before being referred to the hospital. Laboratory analysis revealed that erythrocyte sedimentation rate (ESR) and C-reactive protein (CRP) were 27 mm/hour and 8.1 mg/L, respectively, and thyroid function tests were within normal limits (Table 1). Thyroid sonography demonstrated the presence of focal thyroiditis, hypoechogenicity, and coarsening in the right lobe of the thyroid gland. COVID-19 infection was ruled out with a negative polymerase chain reaction (PCR) test by nasopharyngeal swab. Based on these findings, SAT was diagnosed, and cefpodoxime 200 mg once daily and oral methylprednisolone 32 mg once daily were prescribed. The symptoms of the patient partially subsided, and treatment was stopped after 2 weeks. The patient did not attend clinical follow-up regularly.

Four weeks after cessation of the treatment, the patient presented to our clinic with complaints of neck pain, fatigue, and hoarseness. There was no history of diarrhea, nausea, vomiting, palpitation, tremor, weight loss, or heat intolerance. The patient has taken the second dose of CoronaVac<sup>®</sup> vaccine 2 weeks before visiting our clinic. On physical examination, body weight was 96.6 kg, height 183 cm, body mass index 28.8 kg/m<sup>2</sup>, temperature 36.7°C, respiratory rate 12/minute, and pulse 80/minute. No visible swelling, erythema, or a local rise of temperature on the thyroid gland was observed. Mild tenderness was present on the palpation of the thyroid gland. Oropharyngeal and otological examinations were within normal limits. Examination of the other systems was unremarkable. Thyroid function tests were within normal limits with the exception of slight elevation of free triiodothyronine (fT3) level and inflammatory markers: thyroid-stimulating hormone: 2.45 mIU/L, fT4: 1.14 ng/dL, fT3: 5.32 pg/mL, ESR:17 mm/hour, CRP:13.2 mg/L, anti-thyroid peroxidase (anti-TPO): 106 IU/mL, and anti-thyroglobulin (anti-Tg): 265 IU/mL (Table 1).

Table 1. Laboratory parameters of the patient.

Laboratory parameters	Previous (2 years before referral)	First referral (0 <sup>th</sup> day)	First control (14 <sup>th</sup> day)	Second referral (45 <sup>th</sup> day)	Follow-up (97 <sup>th</sup> day)
ESR (0-20 mm/hour)	NA	38	27	17	3
CRP (0-8 mg/L)	NA	7.8	8.1	13.2	4.4
WBC (3,600-10,200/mm <sup>3</sup> )	NA	6,160	7,000	6,400	6,300
PMNL (43.5-73.5%)	NA	61.4	56.4	60.2	53
TSH (0.27-4.20 mIU/L)	3.33	2.33	1.66	2.45	30.08
fT4 (0.93-1.70 ng/dL)	1.18	1.34	0.96	1.14	0.87
fT3 (2-4.40 pg/mL)	3.54	NA	NA	5.32	3.36
Anti-TPO (0-75 IU/mL)	NA	NA	NA	106	NA
Anti-Tg (0-150 IU/mL)	NA	NA	NA	265	NA
FBG (70-110 mg/dL)	NA	111	NA	100	89
HbA1c (4-5.7%)	NA	NA	NA	NA	5.4
eGFR (mL/min)	NA	0.94	1.02	105	93
ALT (0-41 U/L)	NA	16	18	12	19
AST (0-40 U/L)	NA	20	19	17	19
COVID-19 PCR	NA	Negative	NA	NA	Negative

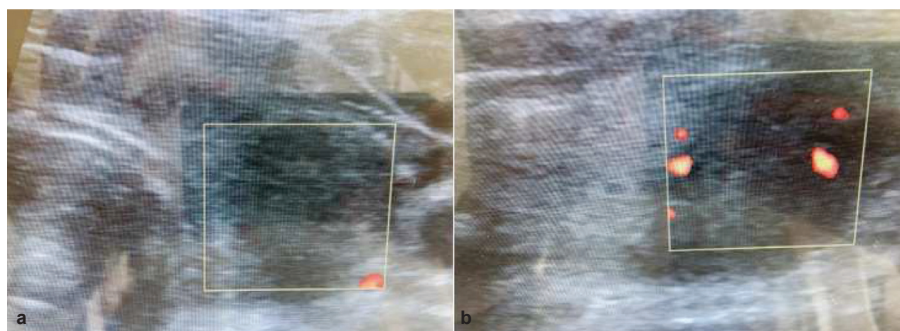
ESR: Erythrocyte sedimentation rate; CRP: C-reactive protein; WBC: White blood cell; PMNL: Polymorphonuclear leukocyte; TSH: Thyroid-stimulating hormone; fT4: Free thyroxine; fT3: Free triiodothyronine; Anti-TPO: Anti-thyroid peroxidase; Anti-Tg: Anti-thyroglobulin; FBG: Fasting blood glucose; HbA1c: Hemoglobin A<sub>1c</sub>; eGFR: Estimated glomerular filtration rate; ALT: Alanine transaminase; AST: Aspartate transaminase; PCR: Polymerase chain reaction; NA: Not available.

On thyroid sonography, diffuse hypoechogenicity and heterogeneity of parenchyma were detected. A hypoechoic, hypovascular, subcapsular area of thyroiditis, with a size of 15.76×17.52×24 mm was detected in the left lobe of the thyroid gland (Figure 1a and 1b).

Based on clinical, laboratory, and sonographic findings, we diagnosed the patient as persistent SAT, which occurred after and was possibly associated with CoronaVac®

vaccination. Ibuprofen 1,200 mg per day was prescribed. Due to mild symptoms and past medical history of avascular necrosis, glucocorticoid was not given.

The patient was re-evaluated after approximately 7 weeks. He has stopped taking ibuprofen after 4 weeks of treatment. The clinical findings, such as pain and tenderness, have been resolved. But the patient complained of fatigue, cold intolerance, weight gain (5 kg), and dry skin for 2-3



**Figure 1.** Sonographic examination of the thyroid gland on the 2<sup>nd</sup> referral (45<sup>th</sup> day), (**1a**: Transverse axis on the left side; **1b**: Longitudinal axis on the right side) demonstrated hypoechoic, hypovascular, subcapsular area of thyroiditis in the left lobe of the thyroid gland.

weeks. Sonographic examination revealed a reduction in the size of the subcapsular area of thyroiditis in the left lobe of the thyroid gland (Figure 2a and 2b). Laboratory evaluation showed the regression of inflammatory markers and overt primary hypothyroidism (Table 1). Oral levothyroxine was given with a gradually increasing dose: 50 mcg/day for 3 days, followed by 75 mcg/day for 3 days, and then 100 mcg/day. The patient was scheduled for re-evaluation after 4 weeks. For this case report, written consent was obtained from the Ministry of Health of Türkiye.

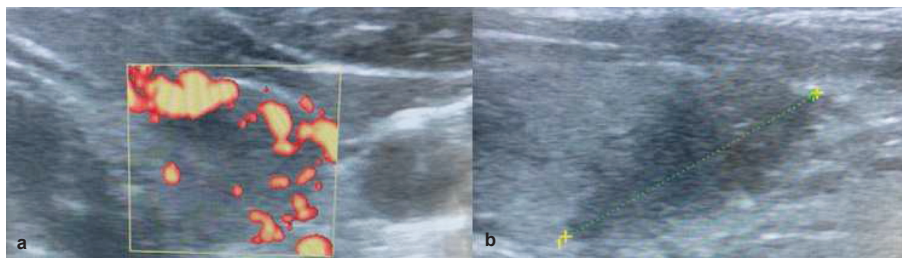
## Discussion

Our report presents a case of persistent SAT, which was diagnosed after the first dose of CoronaVac® vaccine administration, and persisted after the second dose as well. SAT, also known as De Quervain's thyroiditis, is characterized by post-viral inflammatory disorder developing after upper respiratory tract infections (26,27). Typical clinical symptoms and signs, such as pain, increase in inflammatory markers, and sonographic findings, may aid diagnosis. Symptoms of thyrotoxicosis may also accompany the clinical picture. COVID-19 infection has been reported to be associated with several types of thyroid dysfunction, such as Hashimoto's thyroiditis or Graves' disease (10). It was demonstrated that ACE2 and transmembrane serine protease 2 expression in the thyroid gland might be responsible for thyroid involvement in COVID-19 infection (11,13). Recently, SAT has also been shown to develop after COVID-19 infection (9,28-32). There is some evidence regarding the development of SAT after antiviral vaccines also (16-21). A few case re-

ports have demonstrated an association between SAT and inactivated, vectored, and mRNA vaccines developed against COVID-19 infection (22-25).

Massive vaccination drives have been carried out worldwide against COVID-19 (1). In Türkiye, vaccination was started in early 2021, initially in health care workers and the elderly population, and subsequently in other age groups (33). The first available vaccine was CoronaVac®, and later, other types of vaccines, such as the mRNA vaccine, were introduced. Turkish citizens were given a chance to choose one of these vaccines. Our patient opted for CoronaVac®. A case of SAT has been reported from Türkiye where the disease manifested after the 2<sup>nd</sup> dose of the CoronaVac® vaccine in an elderly patient with no history of COVID-19 infection (22). Our patient had suffered a COVID-19 infection 8 months ago. Hence, it may raise a doubt whether the development of SAT in this patient resulted from COVID-19 infection or not. Although it is known that classically SAT occurs 2-8 weeks after an episode of upper respiratory tract infection, recent research has shown that SAT can develop 3-5 weeks after COVID-19 infection (28,34,35). Moreover, the PCR test for COVID-19 was negative in our patient both at the time of the first consultation and on follow-up. Based on these findings, we can exclude the possibility of association of SAT with prior COVID-19 infection, and we propose that the viral antigens in the vaccine triggered SAT in the present case.

SAT is usually treated with nonsteroidal anti-inflammatory drugs and/or glucocorticoids, and sometimes a beta-blocker is added to relieve the symptoms of thyrotoxicosis (26). These medications also decrease the symp-



**Figure 2.** Sonographic examination of the thyroid gland on follow-up (97<sup>th</sup> day), (2a: Transverse axis on the left side; 2b: Longitudinal axis on the right side) demonstrated a small decrease in the size of the area of thyroiditis in the left lobe of the thyroid gland.

toms of SAT developing after COVID-19 infection (28). Ibuprofen, paracetamol, and methylprednisolone are also known to be effective in the symptomatic treatment of SAT associated with the COVID-19 vaccines (22-24). The patient was successfully treated with methylprednisolone in the first referral and with ibuprofen in the second referral. Owing to the history of avascular necrosis of the hip, beta-blocker therapy was not added to the treatment. Our case did not show clinical signs or laboratory findings suggestive of thyrotoxicosis despite a mild elevation of FT3 level in the second visit.

Previous case reports have verified that SAT can develop in the first or second week after the COVID-19 vaccination (22,24,36). In our patient, SAT occurred 1 week after the first dose of the vaccine, and he presented with persistent SAT 2 weeks after the second dose of the vaccine. Symptoms of SAT developing after the COVID-19 vaccination appear to be similar to the SAT resulting from other antiviral vaccines (24). Recurrence of SAT after its first episode can manifest both in the short-term and long-term, as presented in earlier studies (37). Recurrence can be attributed to a relatively short course of glucocorticoid therapy used in treatment (38). Although in our patient there was the persistence of clinical signs and symptoms rather than recurrence, we assume premature cessation of glucocorticoid therapy after the first episode of SAT could be responsible for this persistence.

Most of the laboratory and radiological findings in the present case (elevated inflammatory markers, hypoechoic areas on sonography) were similar to those published in previous reports on post-viral SAT or SAT developing after COVID-19 infection or the COVID-19 vaccination (22-25,28). However, contrary to the earlier studies, neither sub-clinical nor overt thyrotoxicosis developed in our case, albeit mild elevation of FT3 level was observed at the second patient visit. Thyroid autoantibodies might be positive in some patients with SAT (39,40). But several studies suggest that thyroid autoantibodies may be negative in most cases of SAT developing after administration of CoronaVac® or vectored vaccine (22-24,36). Though anti-TPO and anti-Tg were positive in our patient, it may be attributed to the persistence of SAT

or the absence of thyrotoxicosis in this case. Overt primary hypothyroidism was detected 8 weeks after the second visit in our patient, which was treated with levothyroxine. Although, Saygılı et al. has reported the development of overt primary hypothyroidism in a patient after resolution of SAT associated with inactivated COVID-19 vaccine despite negative thyroid autoantibodies (36). We attribute hypothyroidism in our patient to be associated with positive thyroid autoantibodies. In most reports, analyzing SAT associated with the COVID-19 vaccination, the patient was not either followed-up long enough to develop hypothyroidism or did not develop hypothyroidism, or an initial hypothyroid phase was followed by euthyroid state (22-24). Several mechanisms have been proposed regarding the development of SAT after the COVID-19 vaccination (22,24). Aluminum hydroxide adjuvant in CoronaVac®, cross-reaction of SARS-CoV-2 proteins in inactivated as well as other vaccines with thyroid antigens, and genetic predisposition may explain the occurrence of SAT after administration of these vaccines to some extent. Autoimmune thyroid disease may be another possible mechanism since our patient demonstrated the presence of thyroid autoantibodies.

In the future, further cases of SAT associated with either COVID-19 infection or its vaccines may emerge. Comparative studies analyzing clinical and laboratory features of such patients and patients with SAT associated with typical viral respiratory tract infections would reveal more comprehensive information about the course of the disease. In conclusion, antiviral vaccines may lead to the development of SAT. Therefore, the clinicians need to be vigilant of the possibility of SAT in the patients receiving various types of antiviral vaccines, including those against COVID-19 infection. Although the mechanism of SAT developing post-COVID-19 vaccination may be distinct from the one not associated with COVID-19 infection or its vaccination, clinical findings and treatment appear to be indistinguishable.

### Authorship Contributions

All authors contributed equally while this study preparing.

## Source of Finance

During this study, no financial or spiritual support was received neither from any pharmaceutical company that has a direct connection with the research subject, nor from a company that provides or produces medical instruments and materials which may negatively affect the evaluation process of this study.

## Conflict of Interest

No conflicts of interest between the authors and/or family members of the scientific and medical committee members or members of the potential conflicts of interest, counseling, expertise, working conditions, share holding and similar situations in any firm.

## Authorship Contributions

All authors contributed equally while this study preparing.

## References

1. World Health Organization [Internet]. [Cited: ]. WHO Coronavirus (COVID-19) Dashboard. Available from: [\[Crossref\]](#)
2. Kazakou P, Paschou SA, Psaltopoulou T, Gavriatopoulou M, Korompoki E, Stefanaki K, Kanouta F, Kassi GN, Dimopoulos MA, Mitrakou A. Early and late endocrine complications of COVID-19. *Endocr Connect.* 2021;10:R229-R239. [\[Crossref\]](#) [\[PubMed\]](#) [\[PMC\]](#)
3. Shang L, Wang L, Zhou F, Li J, Liu Y, Yang S. Long-term effects of obesity on COVID-19 patients discharged from hospital. *Immun Inflamm Dis.* 2021; 9:1678-1685. [\[Crossref\]](#) [\[PubMed\]](#) [\[PMC\]](#)
4. Haymana C, Demirci I, Tasci I, Cakal E, Salman S, Ertugrul D, Ata N, Unluturk U, Dagdelen S, Atmaca A, Sahin M, Celik O, Demir T, Emral R, Sahin I, Caglayan M, Satman I, Sonmez A. Clinical outcomes of non-diabetic COVID-19 patients with different blood glucose levels: a nationwide Turkish study (TurCoGlycemia). *Endocrine.* 2021;73:261-269. [\[Crossref\]](#) [\[PubMed\]](#) [\[PMC\]](#)
5. Sonmez A, Demirci I, Haymana C, Tasci I, Dagdelen S, Salman S, Ata N, Sahin I, Emral R, Cakal E, Atmaca A, Sahin M, Celik O, Demir T, Ertugrul D, Unluturk U, Caglayan M, Satman I. Clinical characteristics and outcomes of COVID-19 in patients with type 2 diabetes in Turkey: A nationwide study (TurCoviDia). *J Diabetes.* 2021;13:585-595. [\[Crossref\]](#) [\[PubMed\]](#) [\[PMC\]](#)
6. Sahin I, Haymana C, Demir T, Demirci I, Tasci I, Atmaca A, Cakal E, Ata N, Emral R, Unluturk U, Ertugrul D, Salman S, Sahin M, Dagdelen S, Celik O, Caglayan M, Satman I, Sonmez A. Clinical Characteristics and Outcomes of COVID-19 Patients with Overweight and Obesity: Turkish Nationwide Cohort Study (TurCObesity). *Exp Clin Endocrinol Diabetes.* 2021. [\[Crossref\]](#) [\[PubMed\]](#)
7. van Zeggeren IE, Boelen A, van de Beek D, Heijboer AC, Vlaar APJ, Brouwer MC; Amsterdam UMC COVID-19 Biobank. Sex steroid hormones are associated with mortality in COVID-19 patients: Level of sex hormones in severe COVID-19. *Medicine (Baltimore).* 2021;100:e27072. [\[Crossref\]](#) [\[PubMed\]](#) [\[PMC\]](#)
8. Mung SM, Jude EB. Interplay between endocrinology, metabolism and COVID-19 infection. *Clin Med (Lond).* 2021;21:e499-e504. [\[Crossref\]](#) [\[PubMed\]](#) [\[PMC\]](#)
9. Feghali K, Atallah J, Norman C. Manifestations of thyroid disease post COVID-19 illness: Report of Hashimoto thyroiditis, Graves' disease, and subacute thyroiditis. *J Clin Transl Endocrinol Case Rep.* 2021;22:100094. [\[Crossref\]](#) [\[PubMed\]](#) [\[PMC\]](#)
10. Lania A, Sandri MT, Cellini M, Mirani M, Lavezzi E, Mazziotti G. Thyrotoxicosis in patients with COVID-19: the THYRCOV study. *Eur J Endocrinol.* 2020;183:381-387. [\[Crossref\]](#) [\[PubMed\]](#)
11. Li MY, Li L, Zhang Y, Wang XS. Expression of the SARS-CoV-2 cell receptor gene ACE2 in a wide variety of human tissues. *Infect Dis Poverty.* 2020;9:45. [\[Crossref\]](#) [\[PubMed\]](#) [\[PMC\]](#)
12. Lazartigues E, Qadir MMF, Mauvais-Jarvis F. Endocrine Significance of SARS-CoV-2's Reliance on ACE2. *Endocrinology.* 2020;161:bqaa108. [\[Crossref\]](#) [\[PubMed\]](#) [\[PMC\]](#)
13. Rotondi M, Coperchini F, Ricci G, Denegri M, Croce L, Ngnitejeu ST, Villani L, Magri F, Latrofa F, Chiovato L. Detection of SARS-COV-2 receptor ACE-2 mRNA in thyroid cells: a clue for COVID-19-related subacute thyroiditis. *J Endocrinol Invest.* 2021;44: 1085-1090. [\[Crossref\]](#) [\[PubMed\]](#) [\[PMC\]](#)
14. Lazarus JH. Silent thyroiditis and subacute thyroiditis. In: Braverman LE, Utiger RD, eds. *The Thyroid: A Fundamental and Clinical Text.* 7<sup>th</sup> ed. Philadelphia; Lippincott Williams & Wilkins, 1996. p.577.
15. Christensen J, O'Callaghan K, Sinclair H, Hawke K, Love A, Hajkovicz K, Stewart AG. Risk factors, Treatment and Outcomes of Subacute Thyroiditis Secondary to COVID-19: A Systematic Review. *Intern Med J.* 2021:10.1111/imj.15432. [\[Crossref\]](#) [\[PubMed\]](#) [\[PMC\]](#)
16. Girgis CM, Russo RR, Benson K. Subacute thyroiditis following the H1N1 vaccine. *J Endocrinol Invest.* 2010;33:506. [\[Crossref\]](#) [\[PubMed\]](#)
17. Altay FA, Güz G, Altay M. Subacute thyroiditis following seasonal influenza vaccination. *Hum Vaccin Immunother.* 2016;12:1033-1044. [\[Crossref\]](#) [\[PubMed\]](#) [\[PMC\]](#)
18. Hsiao JY, Hsin SC, Hsieh MC, Hsia PJ, Shin SJ. Subacute thyroiditis following influenza vaccine (Vaxigrip) in a young female. *Kaohsiung J Med Sci.* 2006;22:297-300. [\[Crossref\]](#) [\[PubMed\]](#)
19. Hernán Martínez J, Corder E, Uzcategui M, Garcia M, Sostre S, Garcia A. Subacute thyroiditis and dyserythropoiesis after influenza vaccination suggesting immune dysregulation. *Bol Asoc Med P R.* 2011;103:48-52. [\[PubMed\]](#)
20. Toft J, Larsen S, Toft H. Subacute thyroiditis after hepatitis B vaccination. *Endocr J.* 1998;45:135. [\[PubMed\]](#)

21. Passah A, Arora S, Damle NA, Reddy KS, Khandelwal D, Aggarwal S. Occurrence of Subacute Thyroiditis following Influenza Vaccination. *Indian J Endocrinol Metab.* 2018;22:713-714. Erratum in: *Indian J Endocrinol Metab.* 2018;22(6):867. [[Crossref](#)] [[PubMed](#)] [[PMC](#)]
22. Şahin Tekin M, Şaylısoy S, Yorulmaz G. Subacute thyroiditis following COVID-19 vaccination in a 67-year-old male patient: a case report. *Hum Vaccin Immunother.* 2021;1-3. [[Crossref](#)] [[PubMed](#)]
23. Oyibo SO. Subacute thyroiditis after receiving the adenovirus-vectored vaccine for coronavirus disease (COVID-19). *Cureus.* 2021;13:e16045. [[Crossref](#)] [[PubMed](#)] [[PMC](#)]
24. İremli BG, Şendur SN, Ünlütürk U. Three cases of subacute thyroiditis following SARS-CoV-2 vaccine: Postvaccination ASIA syndrome. *J Clin Endocrinol Metab.* 2021;106:2600-2605. [[Crossref](#)] [[PubMed](#)] [[PMC](#)]
25. Bornemann C, Woyk K, Bouter C. Case report: Two cases of subacute thyroiditis following SARS-CoV-2 vaccination. *Front Med (Lausanne).* 2021; 8:737142. [[Crossref](#)] [[PubMed](#)] [[PMC](#)]
26. Ross DS, Burch HB, Cooper DS, Greenlee MC, Laurberg P, Maia AL, Rivkees SA, Samuels M, Sosa JA, Stan MN, Walter MA. 2016 American Thyroid Association Guidelines for Diagnosis and Management of Hyperthyroidism and Other Causes of Thyrotoxicosis. *Thyroid.* 2016;26:1343-1421. Erratum in: *Thyroid.* 2017;27:1462. [[Crossref](#)] [[PubMed](#)]
27. Sweeney LB, Stewart C, Gaitonde DY. Thyroiditis: an integrated approach. *Am Fam Physician.* 2014;90:389-396. [[PubMed](#)]
28. Ünübol M, Erdemir Z, Çolak G, Ünsal MG, Güney E. Subacute thyroiditis associated with COVID-19 infection: Two case reports. *Turk J Endocrinol Metab.* 2021;25:344-348. [[Crossref](#)]
29. Brancatella A, Ricci D, Viola N, Sgrò D, Santini F, Latrofa F. Subacute thyroiditis after Sars-COV-2 infection. *J Clin Endocrinol Metab.* 2020;105: dgaa 276. [[Crossref](#)] [[PubMed](#)] [[PMC](#)]
30. Ippolito S, Dentali F, Tanda ML. SARS-CoV-2: a potential trigger for subacute thyroiditis? Insights from a case report. *J Endocrinol Invest.* 2020;43:1171-1172. [[Crossref](#)] [[PubMed](#)] [[PMC](#)]
31. Asfuroglu Kalkan E, Ates I. A case of subacute thyroiditis associated with Covid-19 infection. *J Endocrinol Invest.* 2020;43:1173-1174. [[Crossref](#)] [[PubMed](#)] [[PMC](#)]
32. Sohrabpour S, Heidari F, Karimi E, Ansari R, Tajdini A, Heidari F. Subacute Thyroiditis in COVID-19 Patients. *Eur Thyroid J.* 2021;9:321-323. [[Crossref](#)] [[PubMed](#)] [[PMC](#)]
33. T.C. Sağlık Bakanlığı [Internet]. [Cited: ]. 10 October 2021. Available from: [[Link](#)]
34. Desailly R, Hober D. Viruses and thyroiditis: an update. *Virology.* 2009;6:5. [[Crossref](#)] [[PubMed](#)] [[PMC](#)]
35. Caron P. Thyroiditis and SARS-CoV-2 pandemic: a review. *Endocrine.* 2021;72:326-331. [[Crossref](#)] [[PubMed](#)] [[PMC](#)]
36. Saygılı ES, Karakılıç E. Subacute thyroiditis after inactive SARS-CoV-2 vaccine. *BMJ Case Rep.* 2021; 14:e244711. [[Crossref](#)] [[PubMed](#)] [[PMC](#)]
37. Stasiak M, Tymoniuk B, Stasiak B, Lewiński A. The risk of recurrence of subacute thyroiditis is HLA-dependent. *Int J Mol Sci.* 2019;20:1089. [[Crossref](#)] [[PubMed](#)] [[PMC](#)]
38. Arao T, Okada Y, Torimoto K, Kurozumi A, Narisawa M, Yamamoto S, Tanaka Y. Prednisolone dosing regimen for treatment of subacute thyroiditis. *J UOEH.* 2015;37:103-110. [[Crossref](#)] [[PubMed](#)]
39. Nishihara E, Amino N, Kudo T, Kohsaka K, Ito M, Fukata S, Nishikawa M, Nakamura H, Miyauchi A. Moderate Frequency of Anti-Thyroglobulin Antibodies in the Early Phase of Subacute Thyroiditis. *Eur Thyroid J.* 2019;8:268-272. [[Crossref](#)] [[PubMed](#)] [[PMC](#)]
40. Sencar ME, Calapkulu M, Sakiz D, Hepsen S, Kus A, Akhanli P, Unsal IO, Kizilgul M, Ucan B, Ozbek M, Cakal E. An evaluation of the results of the steroid and non-steroidal anti-inflammatory drug treatments in subacute thyroiditis in relation to persistent hypothyroidism and recurrence. *Sci Rep.* 2019; 9:16899. [[Crossref](#)] [[PubMed](#)] [[PMC](#)]