

# Three Cases of Lingual Thyroid and Review of the Literature

Haluk Sargın\*

Gökhan Kabacam\*\*

Osman Köseoğulları\*\*

Arif Şanlı\*\*\*

Murat Faik Erdoğan\*\*

\* Kartal Education and Research Hospital, Endocrinology and Metabolic Disease Unit of I. Internal Medicine, Istanbul, Turkey

\*\* Ankara University, Endocrinology and Metabolic Disease, Ankara, Turkey

\*\*\* Kartal Education and Research Hospital, Ear, Nose and Throat, Istanbul, Turkey

**Ecotopic thyroid is a rare clinical entity which has an incidence varying between 1/3000 to 1/10000. Lingual localization accounts for 90% of the ectopia of thyroid gland. Lingual thyroid was found in up to 10 % of autopsy cases. Therefore, it should always be kept in mind in patients with midline masses in the neck especially at the dorsum of their tongue. In this manuscript, we present three cases of the lingual thyroid in the light of the published articles.**

**Key words: Ectopia of thyroid gland, lingual thyroid**

## Introduction

Ectopia of the thyroid gland is a rare clinical entity which has an incidence varying between 1/3000 to 1/10000, with a male-female ratio of 1/4-1/7 (1). It is due to the defect in the migration of embryonic thyroid anlage between 3rd and 7th weeks of gestation, resulting in the ectopic localization of the gland (2). Lingual localization accounts for 90% of the ectopic thyroid tissue and it is first described by Hickman in 1869 (3). Other possible sites of ectopia are sublingual, thyroglossal, intralaryngotracheal, mediastinal, esophageal, heart and cervical lymph nodes (2, 4-9).

## Case Reports

**Case 1:** 29 years old female patient attended to our clinic with complaints of dysphagia, malaise, fatigue, cold intolerance, and weakness of hair. She didn't have any major or chronic illness. In the physical examination, tan to pink colored waxy mass, which is 2.5x2.5cm in size, could be seen at the dorsum of the tongue (Figure 1).

Thyroid gland could not be palpated in its usual location.

### Correspondence address:

Haluk Sargın  
Gözenç Sok. No: 7/13  
Ali Bey Apt. Kantarcı, Erenkoy  
Tel : 0216 441 39 00 / 11 73 – 11 15  
Fax : 0 216 368 48 95  
E-mail : haluksargin@hotmail.com

Routine biochemical analysis revealed, fT4: 0.67 ng/dl (0.8-1.8), fT3: 2.67 ng/L (1.82-4.55), sTSH: 8,62 mIU/ml (0,35-5,5). In the ultrasonographical examination, thyroid gland was not seen at usual pretracheal location, but in left sublingual region 28x26mm hypoechoic mass including cystic areas was found. In the computed tomography a 20x16 mm homogeneous soft tissue mass at the dorsum of the tongue was reported (Figure 2).

Scanning with Tc-99m Pertechnetate showed no activity in the thyroid gland region, however strong lingual activity was reported (Figure 3, Figure 4).

She was prescribed 150mcg levothyroxine but mass symptoms reside and surgical extirpation through transoral route was performed. Replacement treatment with 150mcg levothyroxine was initiated.

**Case 2:** A 16 years old girl complaining of a sublingual mass and hoarseness of her voice after an acute tonsillopharyngitis was referred to the clinic. In the physical examination a 4x5 cm mass was seen at the dorsum of her tongue reaching to valvular recess. Biochemical analysis revealed, fT4: 1.15 ng/dl (0.8-1.8), fT3: 1.72 ng/L (1.82-4.55), TSH: 17.1 mIU/ml (0,35 – 5,5).

Ultrasonography of the neck revealed no thyroid gland at the usual anatomical site, a heterogeneous parenchymal tissue of 40x50mm in size localized sublingually, showing activity in scintigraphic

## CASE REPORT

examination. In Computed Tomography (CT) scan of the neck a sublingual mass of 27x23 mm which is heterogeneous, hyper dense, well demarcated and having contrast enhancement was seen. 100 mcg/day L-thyroxine suppression treatment was given thence the symptoms disappear in 2 months and mass decreased in size.

### Case 3:

A 3.5 months old female infant with complaints of diarrhea, vomiting and abdominal distention was internalized with the diagnosis of acute gastroenteritis and urinary tract infection. She was a post term infant (43 wks) whose parents were 2nd degree relatives. Her mother was diagnosed as gestational diabetes during pregnancy. On her physical examination height, weight and head circumference were on the average percentiles for age. She had stridor and dyspnea with suprasternal and subcostal retractions. Biochemical analysis revealed, fT3: 4.47 ng/L (1.82-4.55), fT4: 0.71 ng/dl (0.8-1.8), TSH: 67.6 mIU/dl (0.35 – 5.5).

In the scintigraphic examination performed for hypothyroidism, there was no activity in usual gland site but in hypo pharyngeal site at midline (Figure 5, Figure 6). For the treatment L-thyroxine 50 mcg/day was given and the symptoms disappeared.

### Discussion

Although it is not frequently encountered by the clinicians, lingual thyroid was found in up to 10% of the autopsy cases, sizes ranging from microscopic to a few centimeters (10).

Underlying etiology of the embryonic defect in migration of the gland is not yet understood but, maternal antibodies against thyroid antigens are thought to be the cause of the arrest in descent of thyroid anlage from its original location at dorsum of the tongue down to final location (11,12).

Most of the cases are asymptomatic but if not, frequently encountered symptoms in patients are due to mass effect, dysphonia, dysphagia, lump in throat sensation, dyspnea, and chronic cough (13). Stridor can be seen especially in the neonates as reported in our case 3. These symptoms can be seen at any time of life having two peaks at 12 and 50 years of age, with a mean of 40.5 years (14). Rarely massive bleeding is encountered, a potentially fatal complication, which is seen more com-

monly in periods of, increased metabolic activity such as, puberty, pregnancy and menses.

Goitrous enlargement, adenomatous and malignant transformation is as common as in eutopic thyroids. Up to date, to our knowledge 29 cases with differentiated carcinoma mostly follicular histology were reported (15). These cases presented with sudden increase in size, ulceration, and bleeding from ulcerated surface of the tumor.

Functionally 30-70% of the reported cases were hypothyroid (2,10), and 70% have cervical athyreosis (16). Only a few cases being hyperthyroid were reported (2).

A careful physical examination, sometimes requiring a device like fiber optic laryngoscope, radiological and scintigraphic techniques is used to evaluate the patients.

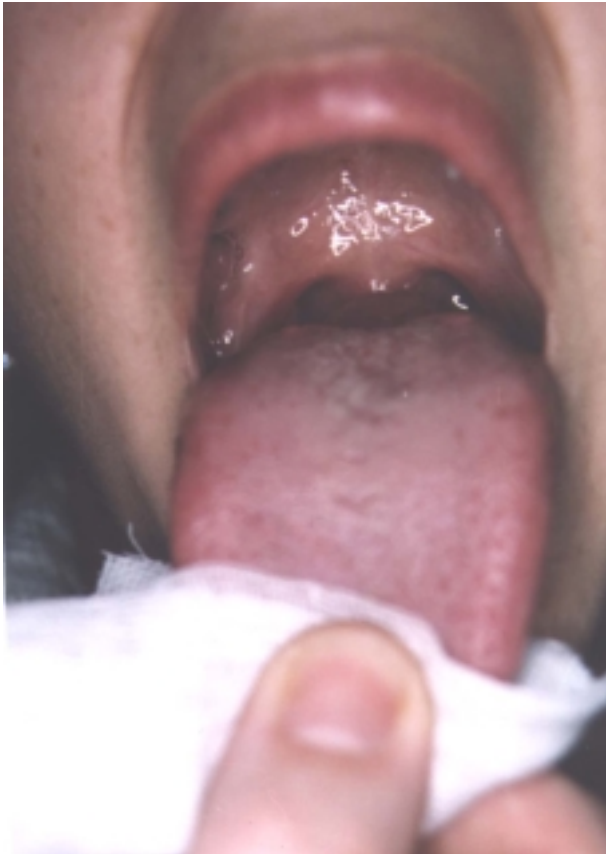Ultrasonography is easy, cost-effective and available in most institutions. Absence of thyroid in usual pretracheal location and presence of the round thyroid tissue at the base of the tongue, sometimes having nodular, cystic changes can be demonstrated. Relations of the gland with surrounding structures can be visualized by this approach (17).

Radio nuclide scanning is the most important radiological approach, radio pharmaceutical uptake of the aberrant tissue mostly Tc-99m helps clinician to discriminate origin of this midline mass and its functional status whereas it alleviates the need of fine needle aspiration biopsy (FNAB)(18).

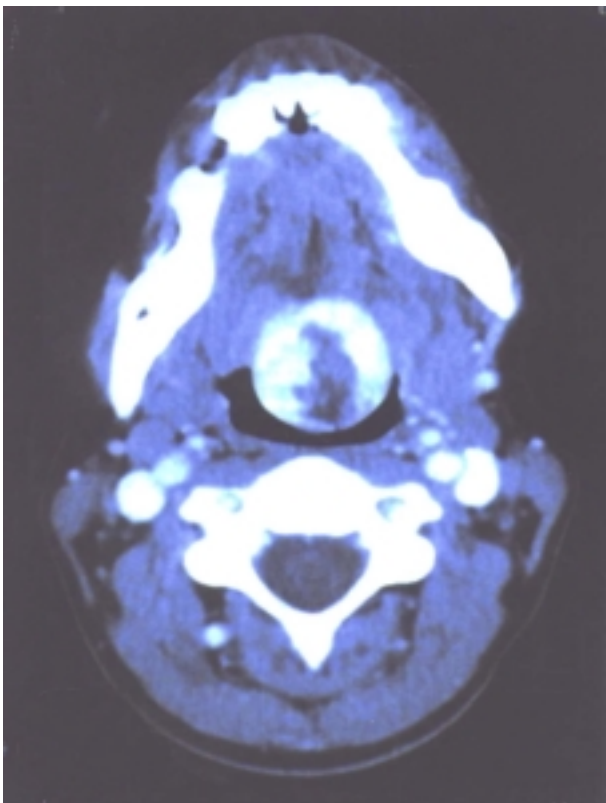
In CT scan, ectopic thyroid tissue usually is hyper dense and has contrast enhancement (19).

Magnetic Resonance Imaging (MRI) can be used to visualize well defined mass of low-intermediate T2 signal in the midline base of the tongue, no invasive tendency, and absence of cervical thyroid gland in the usual pretracheal site strongly indicates the diagnosis (20). Well-defined margins of lingual thyroid on MRI help to differentiate it from malignant masses like non-Hodgkin lymphoma seen at same site. Some authors suggest MRI is the best pre-operative modality providing multiplanar imaging (16).

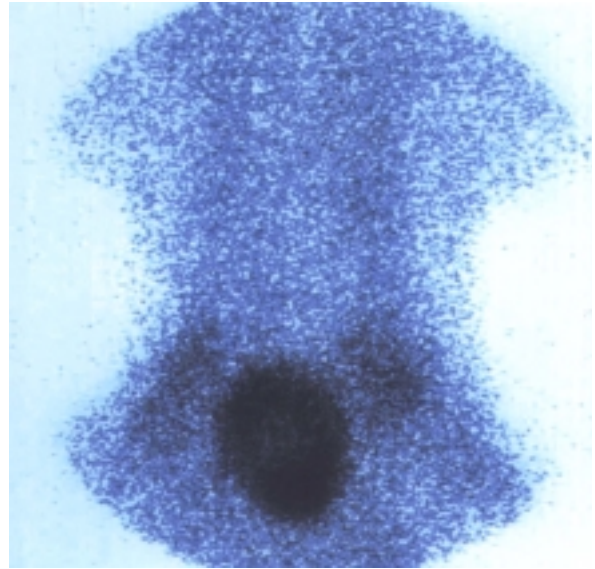
FNAB is not recommended due to frequent complication of bleeding (16).



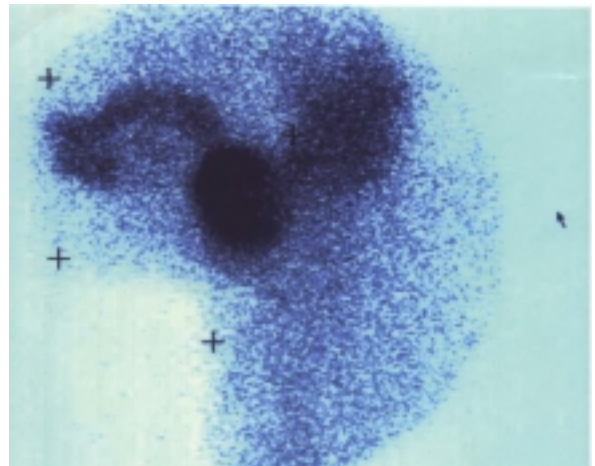
**Figure 1.** Tan to pink colored waxy mass which is 2,5x2,5cm in size could be seen at the dorsum of the tongue.



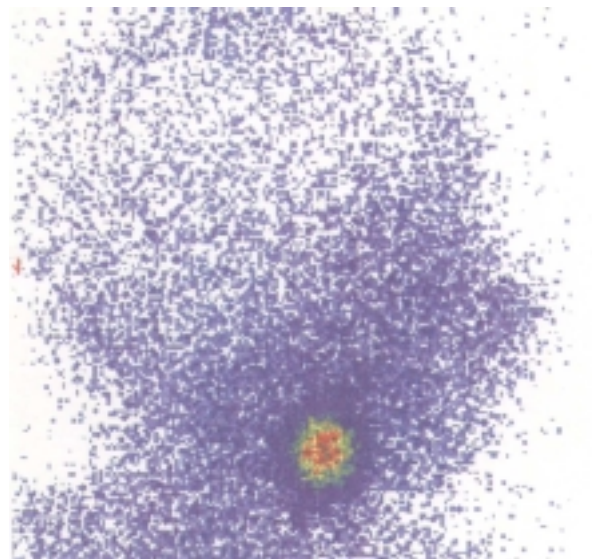
**Figure 2.** 20x16mm homogeneous soft tissue mass at the dorsum of the tongue.



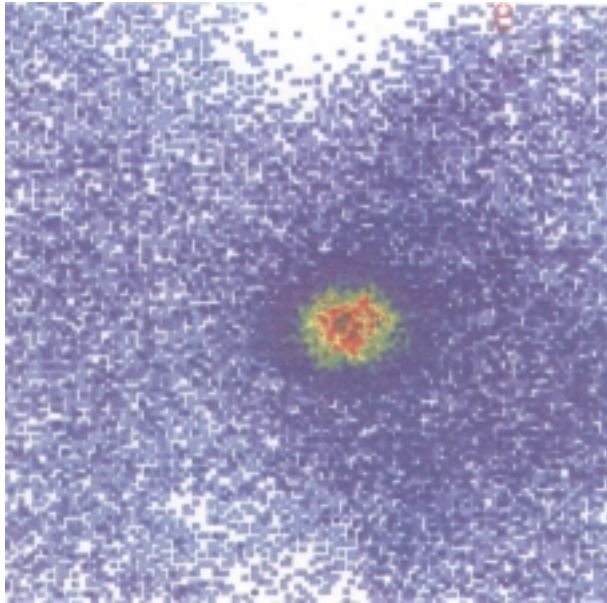
**Figure 3.** Tc-99m Pertechnetate scintigraphy of lingual thyroid, lateral view.



**Figure 4.** Tc-99m Pertechnetate scintigraphy of lingual thyroid, antero-posterior view.



**Figure 5.** Tc-99m Pertechnetate scintigraphy of hypo pharyngeal thyroid, lateral view.



**Figure 6.** Tc-99m Pertechnetate scintigraphy of hypo pharyngeal thyroid, antero-posterior view.

Depending on the patient's symptomatology and functional status of thyroid, asymptomatic cases are followed if they are euthyroid. Thyroid hormone replacement or suppression therapy is required only for the patients having mass symptoms or hypothyroidism. Suppression therapy is used to decrease size and to relieve mass symptoms. If there is excessive discomfort due to mass, bleeding or rapid increase in size of the gland-arising suspicion of malignancy, necessitates surgical removal of the tissue, making pathological examination available (16). Because pregnancy increases the bleeding tendency, emergency lingual artery embolisation or surgery can be necessary to stop bleeding (14). There is no consensus in the surgical approach but trans-oral or external routes can be chosen. Trans-oral route is simpler and causes less pain, whereas external approach is preferred in large, posterior and deeply localized masses (16). One more challenge in the patients undergoing surgery is for anesthesia. Intubation of patients can be difficult and emergency tracheostomy could be necessary (21,22).

In the past radio nuclide ablation was not a popular modality because of theoretical fears of increased airway obstruction due to thyroiditis, but recently it is reported to be safe and effective and could be included in the treatment plan, in especially elder patients who cannot tolerate surgical approach (23). However there are some reports that ectopic

thyroid is more radio resistant and higher doses like 360mCi may be needed for ablation (24).

After surgical or radio nuclide ablation of the gland, L-thyroxine replacement therapy should be instituted.

### Conclusion

Lingual thyroid is a rare clinical entity but is potentially underdiagnosed. It should always be kept in mind in patients with midline masses in the neck especially at the dorsum of their tongue and a planned diagnostic and therapeutic workup should be undertaken.

### References

1. Gallo A, Leonetti F, Torri E, et al. Ectopic lingual thyroid as unusual cause of severe dysphagia. *Dysphagia* **16**(3): 220-3, 2001.
2. Abdallah-Matta MP, Dubarry PH, Pessey JJ, et al, Lingual thyroid and hyperthyroidism: a new case and review of the literature. *J Endocrinol Invest Mar*; **25**(3): 264-7, 2002.
3. Hickman W, Congenital tumour of the base of the tongue, pressing down the epiglottis on the larynx and causing the death by suffocation sixteen hours after birth. *Trans Pathology Soc London*; **20**: 160-63, 1869.
4. Donegan JO, Wood MD. Intratracheal thyroid-Familial occurrence. *The laryngoscope* **95**(2): 66-68.
5. Arriaga MA, Myers EN. Ectopic thyroid in the retro esophageal superior mediastinum. *Otolaryngol Head Neck Surg* **99**: 338-40, 1988.
6. Baughman RA. Lingual thyroid and lingual thyroglossal tract remnants. A clinical and histopathologic study with review of the literature. *Oral Surg Oral Med Oral Pathol* **34**: 781-99, 1972.
7. Pollice L, Caruso G. Struma cordis:ectopic thyroid goiter in the right ventricle. *Arch Pathol Lab Med* **110**: 452-53, 1986.
8. Noyek AM, Friedberg J. Thyroglossal duct and ectopic thyroid disorders. *Otolaryngol Clin North Am* **14**: 187-201, 1982.
9. Postlethwait RW, Detmer DE. Ectopic thyroid nodule in the esophagus. *Ann Thorac Surg* 1975;**19**:98-100.
10. Sauk JJ. Ectopic lingual thyroid. *J Pathol* **102**: 239-43, 1970.
11. Van Der Gaag RD, Drexhage HA, Dussault JH. Role of maternal immunoglobulins blocking TSH induced thyroid growth in sporadic forms of congenital hypothyroidism. *Lancet* **1**: 1246-50, 1985.
12. Arancibia P, Veliz J, Barria M, et al, Lingual thyroid: report of three cases. *Nov* **8**(11): 1055-7, 1998.
13. Oppenheimer R. Lingual thyroid associated with chronic cough. *Otolaryngol Head Neck Surg Oct*; **125**(4): 433-4, 2001.

14. Chiu TT, Su CY, Hwang CF, et al. Massive bleeding from
15. an ectopic lingual thyroid follicular adenoma during pregnancy. *Am J Otolaryngol* May-Jun; **23**(3): 185-8, 2002.
16. Danner C, Bodenner D, Breau R. Lingual thyroid: iodine 131: a viable treatment modality revisited. *Am J Otolaryngol* 2001 Jul-Aug; **22**(4): 276-81.
17. Prasad KC, Bhat V. Surgical management of lingual thyroid: a report of four cases. *J Oral Maxillofac Surg* Feb; **58**(2): 223-7, 2000.
18. Gupta P, Maddalozzo J. Preoperative sonography in presumed thyroglossal duct cysts. *Arch Otolaryngol Head Neck Surg* **127**: 200-02, 2001.
19. Aktolun C, Demir H, Berk F, et al. Diagnosis of complete ectopic lingual thyroid with Tc-99m pertechnetate scintigraphy. *Clin Nucl Med* Nov; **26**(11): 933-5, 2001.
20. Willinsky RA, et al. Computed tomography of lingual thyroid. *J Comput Assist Tomogr* **11**: 182-83, 1987.
21. Takashima S, Ueda M, Shibata A, et al. MR imaging of the lingual thyroid. Comparison to other submucosal lesions. *Acta Radiol* Jul; **42**(4): 376-82, 2001.
22. Palmer JH, Ball DR. Lingual thyroid--another potential airway threat. *Anaesthesia* Apr; **56**(4): 386, 2001.
23. Buckland RW, Pedley J. Lingual thyroid--a threat to the airway. *Anaesthesia* Nov; **55** (11): 1103-5, 2000.
24. Danner C, Bodenner D, Breau R. Lingual thyroid: iodine 131: a viable treatment modality revisited. *Am J Otolaryngol* Jul-Aug; **22**(4): 276-81, 2001.
25. Ramos-Gabatin A, Pretorius HT. 1985 Radionuclide turnover studies on ectopic thyroid glands--case report and survey of the literature. *J Nucl Med* **26**: 258-62.