



Complications of Stump Healing Among Diabetic Population

Diyabetik Populasyonda Gdk Yarası Komplikasyonları

^{ib}Suhel Ashraff, ^{ib}Muhammad A. Siddiqui, ^{ib}Derek Santos, ^{**ib}Thomas Carline^{**}

Department of Diabetes and Endocrinology, Royal Victoria Infirmary, Newcastle, UK
*Research and Performance Support, Saskatchewan Health Authority, Regina, Canada
^{**}School of Health Sciences, Queen Margaret University, Edinburgh, UK

Abstract

Lower limb amputation is a major procedure performed in diabetic patients with multiple comorbidities. Almost 10% of the National Health Service budget is taken up by diabetes, with diabetes-related complications accounting for 80% of the costs. The process of wound healing is complex and involves regenerating the cellular organization and the tissue layers. Diabetics are five times more predisposed to wound infection than patients without diabetes mellitus. The amputated stump frequently becomes infected due to inadequate blood circulation, a weak immune system, and poorly controlled diabetes mellitus. Pain, stump edema, and osteomyelitis are significant complications associated with lower limb amputation wounds. A number of factors may substantiate the need for re-amputation, such as stump pain and/or phantom limb pain, delayed stump infection, the formation of symptomatic bone spurs, assessment of the skin flap designed to preserve stump length, and preparation of the stump for the prosthetic device. There are currently no reliable standards that can be referred to prior to leg amputation. The clinicians, therefore, have to rely on their judgment and investigatory parameters. The main purpose of this review is to discuss the difficulties of stump healing in the diabetic population.

Keywords: Diabetes; complication; leg amputation; stump healing

zet

Alt ekstremite amptasyonu, eşlik eden birden fazla hastalığı olan diyabetik hastalarda yapılan önemli bir işlemdir. Ulusal sađlık hizmetleri) btcesinin hemen hemen %10'u diyabet tarafından kullanılmakta olup, bu maliyetin %80'inden diyabete bađlı komplikasyonlar sorumludur. Yara iyileşmesi karmaşık bir süreçtir ve hresel organizasyon ve doku tabakalarının yeniden oluşumunu kapsamaktadır. Diyabetik hastalar, diabetes mellitusu olmayan hastalara kıyasla yara enfeksiyonuna beş kat daha fazla yatkındır. Amptasyon gdđ ise, yetersiz kan dolaşımı, zayıf bir bađışıklık sistemi ve kontrol altına alınamamış diabetes mellitus nedeni ile sıklıkla enfekte olmaktadır. Ađrı, gdk demi ve osteomyelit alt ekstremite amptasyon yaraları ile ilişkili en önemli komplikasyonlardır. Gdk ađrısı ve/veya hayalet ekstremite ađrısı, ge gdk enfeksiyonu, semptomatik kemik mahmuzu oluşumu, gdk uzunluđunu korumak iin tasarlanan deri flebinin deđerlendirilmesi ve gdđn protez iin hazırlanması gibi faktrler yeniden amptasyon yapılması iin ihtiya yaratabilmektedir. Gnmzde, bacak amptasyonu ncesi bařvurulacak gvenilir standartlar bulunmamaktadır. Bu nedenle klinisyenler, kendi yargılarına ve incelenen parametrelere gvenmek durumundadır. Bu alıřmada, diyabetik populasyonda gdk yarası iyileşmesinin komplikasyonlarının tartıřılması amalanmıřtır.

Anahtar kelimeler: Diyabet; komplikasyon; bacak amptasyonu; gdk iyileşmesi

Introduction

Between 2006-2011, the number of people diagnosed with diabetes mellitus (DM) has increased by 25% in the UK alone, from 1.9 million to 2.5 million (1). Furthermore, the number of people with undiagnosed DM is estimated to be around 850,000. Based on the existing trends, the num-

ber of diabetics in the UK is expected to reach 5 million by 2025. Type 2 DM is more prevalent (90%) than type 1 DM (10%) (2). Concomitantly, DM-related complications like amputations, stroke, blindness, and end-stage kidney failure are also on the rise and are life threatening with a high mortality rate. Schofield et al. (3) reported

Address for Correspondence: Muhammad A. Siddiqui, Research and Performance Support, Saskatchewan Health Authority, Regina, Canada

Phone: 306-519-4485 **E-mail:** drasadi@hotmail.com **Received:** 24.01.2018 **Accepted:** 26.03.2018

©Copyright 2018 by Turkish Journal of Endocrinology and Metabolism Association
Turkish Journal of Endocrinology and Metabolism published by Trkiye Klinikleri

that the median time to death following lower limb amputation was higher in patients with DM than in healthy controls (27.2 months vs. 46.7 months, $p=0.01$). In addition, the study also found that patients with DM had a higher risk of developing congestive heart disease or needing an amputation by factors of 2.26 (95% CI 1.12-4.5) and 1.95 (95% CI 1.14-3.33), respectively. Diabetic foot disease often leads to serious long-term complications, resulting in significant socio-economic and healthcare burdens. The UK National Health Service (NHS) is under enormous financial strain as a result of diabetic foot complications, which is reflected in greater outpatient costs, bed occupancy, and extended hospitalization. The cost of diabetic foot care to the NHS during 2010-2011 was £639-662 million.

The ability and the time required for a patient to walk with a prosthetic limb after a lower limb amputation is determined largely by the process of wound healing (4). In addition, the type of treatment wound characteristics and the condition of the patient also affect the stump healing process. Pino et al. (5) reviewed 19 studies on lower limb amputation in patients with DM and concluded that a complete preoperative workup is desirable before an amputation with emphasis on the probable rate of healing, the functional condition of the limb prior to surgery, control or treatment of any additional diseases, and selection of the level of amputation based on latest techniques. The main purpose of this study was to discuss the problem of stump healing in the diabetic population.

Types of Healing

Amputations are considered to have healed primarily if the wound healed without additional debridement or revision. Longer wound healing that prevents prosthetic fitting for at least three months, but eventually leads to closure of the wound is classified as "delayed." When amputations are complicated by wound necrosis or severe infection, leading to repeated surgery, the wound healing is classified as "failed" (6). The process of wound healing is complex and entails regenerating the cellular organization and the tissue layers. Mercandetti et al. (6) have classified the wound healing process into three categories: 1) category 1 healing, also known as primary wound healing or healing by the first intention, results in minimum damage to cellular structures, 2) category 2 or delayed primary wound healing occurs when the margins of the wound

are not reconfigured promptly and may prove beneficial if the wound becomes infected, and 3) category 3 or secondary healing allows a full-thickness wound to close and heal on account of extensive inflammation which stimulates the wound to recede.

Complications of Stump Healing

Lower limb amputation surgery is frequently performed in patients who have multiple comorbidities. A large number of patients with DM are hospitalized due to lower limb-related problems (7) such as infection, pain, and osteomyelitis (Figure 1). McIntosh et al. (8) carried out a retrospective study from 2005 to 2007 on 231 patients who underwent major amputations of lower extremities. They observed that 7.3% of the patients experienced wound infection, phantom pain, poor body image, depression and myocardial infarction following the amputations. Diabetics are twice more likely to experience congestive cardiac failure and deep vein thrombosis (DVT; 11% risk) after amputation than patients without DM (3).

Infection of the Stump

Patients who have undergone amputation can develop severe problems as a result of infections, especially if they suffer from DM. The amputated stump frequently becomes infected requiring re-amputation (9). The wound infection rates following major lower limb amputation vary between 13% and 40%. Methicillin-resistant *Staphylococcus aureus* (MRSA) is the most common cause of post-amputation infections (10, 11). The morbidity and mortality rates usually in-

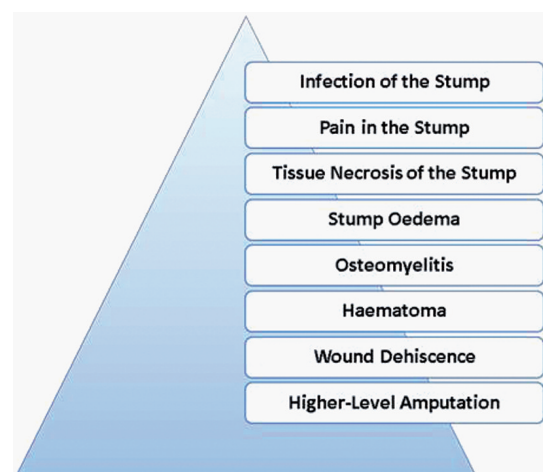


Figure 1: Major complications of stump healing.

crease as a result of MRSA infection in vascular patients (12-14).

As indicated by Ray (15), patients with DM are five times more predisposed to wound infections than patients without DM, and the presence of peripheral vascular disease further increases the risk of infection. In a study by Aulivola et al. (16), an infection develops in 5.5% of trans-tibial and 6.7% of trans-femoral amputations. A wound infection can produce excessive amounts of discharge that disrupt the suture line (17), and Baxter (18) showed that an extensive infection can even cause wound rupture and tissue death, thus requiring additional surgical interventions. According to the Infection Surveillance Service in England (2006), leg amputations are associated with the highest risk of infection since a large number of patients are subjected to this procedure as a consequence of severely infected ulcerations. Additionally, a number of factors such as inadequate blood circulation, a weak immune system, and poorly controlled DM may increase the likelihood of infection.

As noted by Grey (19), cellulitis is another problem which can accompany leg amputation and manifests as inflammation, pain, pus formation, redness, heat, and pyrexia. Serious cases of cellulitis progress to septicemia. The use of prophylactic antibiotics has reduced the incidences of wound infection and cellulitis, resulting in a decline in not only the rate of infection but also in the rate of re-amputation (8). Therefore, it is crucial to ensure effective treatment of wound infections to aid the healing process and to minimize the morbidity and mortality rates.

Pain in the Stump

Pain is a significant and complex problem accompanying lower limb amputation. Incision stump pain and phantom limb pain are the two kinds of pain that amputees experience. Stump pain is limited to the area closely surrounding the stump and amputation site (20). If left untreated, it can adversely influence the wound healing process and consequently, reduce the patient's quality of life. Opiates and non-steroidal anti-inflammatory agents have been shown to alleviate stump pain. According to Chan et al. (21), 90% of amputees experience phantom limb pain, which has been described as a crushing, tearing pain which the patients feel in the amputated limb (22). Phantom limb pain occurs after amputation and can endure for a few years or, in rare cases, for the rest of a patient's life (20).

Tissue Necrosis of the Stump

As a large number of amputations are performed due to ischemia, inadequate circulation in the stump area can cause tissue necrosis, which manifests as changes in skin color, dry gangrene, or wet gangrene. Ray (15) pointed out that changes in skin color around the incision line can indicate wound rupture following surgical intervention, or even tissue death a number of weeks after the procedure.

Debridement is a frequently used technique to accelerate wound healing (23). Low amounts of dead tissue are usually left to the natural process of autolysis, once it is ascertained that they are harmless. In cases of significant necrosis, however, wound debridement is preferred. The decision as to the optimum method for dead tissue removal (24) depends on a number of factors such as convenience, wound type, location, and costs (25). Larval therapy, which uses sterile maggots, is a frequently used debridement method in the UK. The popularity of this method is attributed to the fact that it is the only viable option in most cases since the presence of comorbidities often prevents surgical intervention or other methods of stump debridement (26).

Stump Edema

Stump edema is a common problem faced by amputees, especially those who are suitable for prosthetic fitting. According to Ray (15), pre-existing venous deficiency, generalized fluid retention due to congestive heart failure and chronic hyper vascularity are some of the factors causing extensive and protracted edema. Hypervascularity is frequently encountered in DM patients without a severely disrupted circulation.

Extensive edema and discharge delay the stump healing process. Scanlon et al. (27) argued that some components of the wound exudates have a negative effect on wound healing, as well as on the surrounding skin. The development and infection of seroma/hematoma are considered to be the causes of exaggerated wound discharge (15). A number of researchers (28, 29) have recommended periodically elevating the amputated leg to limit edema around the stump area. The appropriate wound dressing is also essential to maintain a good moisture level within the wound. Banwell et al. (30) have suggested that topical negative pressure on discharging stump wounds can stimulate fluid elimination and thus decrease the risk of edema (31). In addition, it is vital to maintaining skin hygiene in patients with edema

as they are more prone to develop infections or even cellulitis due to impaired cellular and lymphatic functions (32). Edema can be reduced by wrapping the stump wound in elastic bandages (33), which protect the healing tissue, keep the dressings in place, limit inflammation and shape the remaining limb, thereby preparing it for the prosthetic device (34).

Limb swelling due to deep vein thrombosis (DVT) often occurs in patients who have undergone leg amputation (35). Apart from DVT, limb swelling can also develop as a result of hypoproteinemia, stump dependency, and infection. It is crucial to determine the exact cause of stump edema in order to prescribe the proper treatment, such as a high protein diet.

Osteomyelitis

Osteomyelitis is a dreaded complication post amputation as it can result in life-threatening sepsis (36). The bone in the amputation area can become exposed through the skin as a result of muscle withdrawal from the stump (15). A ruptured wound can facilitate bone exposure, increasing the risk of osteomyelitis. Surgical intervention is needed if the area of exposed bone is extensive, and the granulation tissue cannot cover it through secondary healing. As noted by Lipsky et al. (37), the diagnosis and treatment of osteomyelitis in patients with DM pose considerable difficulties and requires the early involvement of a multidisciplinary team. Diabetes-related osteomyelitis is diagnosed based on clinical, biochemical and radiological evidence as well as findings of some bedside test. It is possible to carry out a probe-to-bone test but its accuracy is doubtful (38, 39). However, the main method used to diagnose osteomyelitis is a microbiological examination of the bone biopsy (40). After initial radiography, magnetic resonance imaging (MRI) is used to assess the development of pedal osteomyelitis and the extent of soft tissue infection, with a sensitivity and specificity of 90% and 83%, respectively (41).

Stump Hematoma

Bale et al (42) defined hematoma as a localized accumulation of blood inside an organ, cavity or tissue. A hematoma provides a suitable environment for the development of infection and can generate dead space, undermining the suture line and expanding the level of tension in the wound (18). Hematomas usually drain freely and do not necessitate surgery. Nevertheless, surgical debridement is used to remove considerable quantities of coagulated blood (15). Morrison et

al. (43) reported an increased likelihood of hematoma formation under the suture line in the case of wounds without drainage, which can lead to the development of tension, edema, and infection. Furthermore, the blood circulation can also be affected by the increased tension under the suture line, causing wound rupture and tissue death (44). A hematoma should be identified using efficient evaluation methods and the patient must be referred to surgery immediately if needed.

Wound Dehiscence

Wound dehiscence refers to the sudden opening of the wound along the suture line and is accompanied by a sharp increase in serosanguineous drainage (45). It usually occurs when the wound is too weak to resist exterior forces such as shear or direct trauma (42), as a result of the premature removal of sutures, or stump edema which creates tension in the wound. Total dehiscence can potentially determine the exposure of muscle and bone (18).

Harker (23) proposed the use of topical negative pressure on the amputated area to prevent wound dehiscence, which has had a higher success rate in previous applications (46). Topical negative pressure therapy, such as the vacuum-assisted closure (VAC) system, can handle extensive quantities of exudates and safeguard the skin against maceration and abrasion, thereby limiting the risk of infection. It also stimulates the generation of granulation tissue inside the cavity wound. The main disadvantage of the topical negative pressure therapy, however, is that many patients cannot tolerate the pain (47). Studies that have discussed the complexity of dehiscent amputation wounds and the difficulties in treating them have recommended the collaboration of different specialists to gain positive results (17).

Non-Healing Requiring a Higher-Level Amputation

Re-amputation refers to a higher level amputation secondary to non-healing of the stump. There are a number of factors which may substantiate the need for re-amputation, such as stump pain and/or phantom limb pain, delayed stump infection, the formation of symptomatic bone spurs, assessment of the skin flap designed to preserve stump length, and preparation of the stump for the prosthetic device. Dillingham et al. (48) observed that re-amputation is more likely to be performed in the diabetics than in patients

without DM. Reiber (49) estimated that 9% to 20% of patients with DM with an initial leg amputation undergo re-amputation within the first year, and 28% to 51% of patients with DM necessitate re-amputation within five years of the original amputation.

Death Following an Inability to Heal Stump

Criqui et al. (50) revealed that the likelihood of amputees with the peripheral vascular disease to die as a result of cardiovascular complications within ten years of the amputation is six times higher than that of amputees without the peripheral vascular disease. Lee et al. (51) reported that the most common cause of death after a lower limb amputation was DM (37.3%), cardiovascular disease (29.1%), and renal disease (7.3%). According to Mayfield et al. (52), the mortality rate among patients with renal disease, cardiovascular disease or proximal amputation level was high during the first 12 months of the procedure. Toursarkissian et al. (53) reported that the mortality rates increased by 23%, 41%, and 80% in the period immediately following the amputation, after one year, and after five years of the procedure, respectively.

The five-year mortality rates associated with above-knee and below-knee amputation were estimated at 90% and 70%, respectively (54). Tentolouris et al. (55) found that 61% of patients with DM aged between 67 and 76 years who had undergone amputation, were likely to die within five years of the operation. Heikkinen et al. (56) reported that the post-amputation mortality rate even among the younger patients with DM was significantly higher than that of non-diabetics. According to Schofield et al. (3), the mortality rate among amputees with DM was 55% higher than among patients without DM. One reason for the high mortality rate may be the greater emphasis on rescuing the limb which delays amputation to only when revascularization is not feasible.

Conclusion

Successful stump healing is a pre-requisite for amputation following a lower limb amputation. This review has provided a detailed evaluation of the risks conferred by some of the key complications of lower limb stump healing. There are currently no reliable standards that can be referred to prior to leg amputation surgery. The clinicians, therefore, have to rely on their own judgment and other investigatory parameters including a pre-operative

angiogram which has a major role in determining the level of amputation. In order to identify which lower limb stumps would heal following a major lower limb amputation, a pre-surgery prediction rule needs to be formulated and verified.

Ethical approval & Informed consent: Not applicable

Source of Finance: During this study, no financial or spiritual support was received neither from any pharmaceutical company that has a direct connection with the research subject, nor from a company that provides or produces medical instruments and materials which may negatively affect the evaluation process of this study.

Conflict of Interest: No conflicts of interest between the authors and / or family members of the scientific and medical committee members or members of the potential conflicts of interest, counseling, expertise, working conditions, share holding and similar situations in any firm.

Authorship Contributions

Idea/Concept: Suhel Ashraff; Design: Suhel Ashraff, Muhammad A. Siddiqui; Control/Supervision: Suhel Ashraff; Analysis and/or Interpretation: Suhel Ashraff, Muhammad A. Siddiqui; Literature Review: Suhel Ashraff, Muhammad A. Siddiqui, Derek Santos; Writing the Article: Suhel Ashraff, Muhammad A. Siddiqui, Derek Santos, Thomas Carline; Critical Review: Derek Santos, Thomas Carline.

References

1. Quality and Outcomes Framework (QOF)-2015-16. In: England; 2016.
2. Diabetes UK. Diabetes in the UK 2011-12 Key Statistics on Diabetes. In: Diabetes UK; 2011.
3. Schofield CJ, Libby G, Brennan GM, MacAlpine RR, Morris AD, Leese GP. Mortality and hospitalization in patients after amputation: a comparison between patients with and without diabetes. *Diabetes Care*. 2006;29:2252-2256.
4. White SA, Thompson MM, Zickerman AM, Broomhead P, Critchley P, Barrie WW, Bell PR. Lower limb amputation and grade of surgeon. *Br J Surg*. 1997;84:509-511.
5. Pino AE, Taghva S, Chapman C, Bowker JH. Lower-limb amputations in patients with diabetes mellitus. *Orthopedics*. 2011;34:e885-892.
6. Mercandetti M, Cohen AJ. Wound Healing and Repair. In: 2017.
7. Boulton AJ, Vileikyte L, Ragnarson-Tennvall G, Apelqvist J. The global burden of diabetic foot disease. *Lancet*. 2005;366:1719-1724.
8. McIntosh J, Earnshaw JJ. Antibiotic prophylaxis for the prevention of infection after major limb amputation. *Eur J Vasc Endovasc Surg*. 2009;37:696-703.

9. de Godoy JM, Ribeiro JV, Caracanhas LA, Godoy Mde F. Hospital infection after major amputations. *Ann Clin Microbiol Antimicrob.* 2010;9:29-34.
10. Pereira de Godoy JM, Vasconcelos Ribeiro J, Caracanhas LA. Mortality and diabetes mellitus in amputations of the lower limbs for gas gangrene: a case report. *Int J Low Extrem Wounds.* 2008;7:239-240.
11. Godoy JMP, Ribeiro JV, Caracanhas LA. Hospital mortality after major amputation of the lower limbs for critical ischemia. *The Open Atherosclerosis & Thrombosis Journal.* 2009;9:24-25.
12. Cowie SE, Ma I, Lee SK, Smith RM, Hsiang YN. Nosocomial MRSA infection in vascular surgery patients: impact on patient outcome. *Vasc Endovascular Surg.* 2005;39:327-334.
13. del Río-Solá ML, San Norberto-García E, González-Fajardo JA, Carrera-Díaz S, Gutiérrez-Alonso V, Vaquero-Puerta C. Methicillin resistant *Staphylococcus aureus* infection postoperative complications and prognosis of patients with lower extremity amputations. *Med Clin (Barc).* 2006;126:129-131.
14. Malde DJ, Abidia A, McCollum C, Welch M. The success of routine MRSA screening in vascular surgery: a nine year review. *Int Angiol.* 2006;25:204-208.
15. Ray RL. Complications of lower extremity amputations. *Topics Emergency Med.* 2000;22:35-42.
16. Aulivola B, Hile CN, Hamdan AD, Sheahan MG, Veraldi JR, Skillman JJ, Campbell DR, Scovell SD, LoGerfo FW, Pomposelli FB Jr. Major lower extremity amputation: outcome of a modern series. *Arch Surg.* 2004;139:395-399.
17. Stringfellow SC, Cooper PJ. Above the knee amputation wound which dehisced following surgery. *Br J Nurs.* 2000;9:S30-32.
18. Baxter H. Management of surgical wounds. *Nurs Times.* 2003;99:66-68.
19. Grey JE. Cellulitis associated with wounds. *J Wound Care.* 1998;7:338-339.
20. Ellis K. A review of amputation, phantom pain and nursing responsibilities. *Br J Nurs.* 2002;11:155-157.
21. Chan BL, Witt R, Charrow AP, Magee A, Howard R, Pasquina PF, Heilman KM, Tsao JW. Mirror therapy for phantom limb pain. *N Engl J Med.* 2007;357:2206-2207.
22. Donohue S, Sutton-Woods P. Lower limb amputation. In: Murray S, ed. *Vascular Disease: Nursing and Management (1st ed).* London: Whurr Publish; 2001;452.
23. Harker J. Wound healing complications associated with lower limb amputation. *World wide wounds.* In: UK; 2006.
24. Flanagan M. *Wound Management.* London: Churchill Livingstone; 1997.
25. Excellence NifHaC. *Diabetic Foot Problems: Inpatient Management of Diabetic Foot Problems. Clinical Guideline 119.* London: NICE; 2013.
26. Jones M, Andrew A, Miller M, Glover D. *Wound Management.* London editors. *Nurs Times.* 1999;129-33.
27. Scanlon E. Moisture balance and exudate control. In: Moore K, ed. *A Journey Through TIME: Wound Bed Preparation in Practice.* 2004;9;18-24.
28. Chalmers R, Tambyraja A. Diabetic foot disease: how are amputations performed? *Diabetic Foot.* 2002;5:170-178.
29. Van Urk H. Above knee amputation. In: Greenhalgh RM, ed. *Vascular and Endovascular Surgical Techniques (4th ed).* London: WB Saunders; 2001. kaynağın toplan sayfa sayısı 548.
30. Banwell PE, Musgrave M. Topical negative pressure therapy: mechanisms and indication. *Int Wound J.* 2004;1:95-106.
31. Ballard JL, Eke CC, Bunt TJ, Killeen JD. A prospective evaluation of transcutaneous oxygen measurements in the management of diabetic foot problems. *J Vasc Surg.* 1995;22:485-490.
32. Casey G. Oedema: causes, physiology and nursing management. *Nurs Stand.* 2004;18:45-51.
33. Bryant G. Stump care. *Am J Nurs.* 2001;101:67-71.
34. Hayes DD. How to wrap a below-the-knee amputation stump. *Nursing.* 2003;33:70.
35. Burke B, Kumar R, Vickers V, Grant E, Scremin E. Deep vein thrombosis after lower limb amputation. *Am J Phys Med Rehabil.* 2000;79:145-149.
36. Kapoor A, Page S, Lavalley M, Gale DR, Felson DT. Magnetic resonance imaging for diagnosing foot osteomyelitis: a meta-analysis. *Arch Intern Med.* 2007;167:125-132.
37. Lipsky BA, Hoey C. Topical antimicrobial therapy for treating chronic wounds. *Clin Infect Dis.* 2009;49:1541-1549.
38. Lavery LA, Armstrong DG, Peters EJ, Lipsky BA. Probe-to-bone test for diagnosing diabetic foot osteomyelitis: reliable or relic? *Diabetes Care.* 2007;30:270-274.
39. Shone A, Burnside J, Chipchase S, Game F, Jeffcoate W. Probing the validity of the probe-to-bone test in the diagnosis of osteomyelitis of the foot in Diabetes. *Diabetes Care.* 2006;29:945.
40. Lipsky BA. Osteomyelitis of the foot in diabetic patients. *Clin Infect Dis.* 1997;25:1318-1326.
41. Schweitzer ME, Daffner RH, Weissman BN, Bennett DL, Blebea JS, Jacobson JA, Morrison WB, Resnik CS, Roberts CC, Rubin DA, Seeger LL, Taljanovic M, Wise JN, Payne WK. ACR appropriateness criteria on suspected osteomyelitis in patients with Diabetes mellitus. *J Am Coll Radiol.* 2008;5:881-886.
42. Bale S, Jones V. *Wound Care Nursing: A Patient-Centred Approach (1st ed).* London: Bailliere Tindall; 1997;235.
43. Morrison M, Moffatt C, Bridel-Nixon J, Bale S. *Nursing Management of Chronic Wounds (2nd ed).* London: Mosby; 1997;298.
44. Partridge C. Influential factors in surgical wound healing. *J Wound Care.* 1998;7:350-353.
45. Heller L, Levin SL, Butler CE. Management of abdominal wound dehiscence using vacuum assisted closure in patients with compromised healing. *Am J Surg.* 2006;191:165-172.
46. Morton N. Use of topical negative pressure therapy in postoperative dehisced or infected wounds. *J Wound Care.* 2004;13:346-348.
47. Armstrong DG, Lavery LA; Diabetic Foot Study Consortium. Negative pressure wound therapy after partial diabetic foot amputation. *Lancet.* 2005;366:1704-1710.

48. Dillingham TR, Pezzin LE, Shore AD. Reamputation, mortality, and health care costs among persons with dysvascular lower-limb amputations. *Arch Phys Med Rehabil.* 2005;86:480-486.
49. Reiber GE. Epidemiology of foot ulcers and amputations in the diabetic foot. In: Bowker JH, Pfeifer MA, eds. *The Diabetic Foot* (6th ed). St. Louis: Mosby; 2001;648.
50. Criqui MH, Langer RD, Fronek A, Feigelson HS, Klauber MR, McCann TJ, Browner D. Mortality over a period of 10 years in patients with peripheral arterial disease. *N Engl J Med.* 1992;326:381-386.
51. Lee JS, Lu M, Lee VS, Russell D, Bahr C, Lee ET. Lower-extremity amputation. Incidence, risk factors, and mortality in the Oklahoma Indian Diabetes Study. *Diabetes.* 1993;42:876-882.
52. Mayfield JA, Reiber GE, Maynard C, Czerniecki JM, Caps MT, Sangeorzan BJ. Trends in lower limb amputation in the Veterans Health Administration, 1989-1998. *J Rehabil Res Dev.* 2000;37:23-30.
53. Toursarkissian B, Shireman PK, Harrison A, D'Ayala M, Schoolfield J, Sykes MT. Major lower-extremity amputation: contemporary experience in a single Veterans Affairs institution. *Am Surg.* 2002;68:606-610.
54. Hambleton IR, Jonnalagadda R, Davis CR, Fraser HS, Chaturvedi N, Hennis AJ. All-cause mortality after diabetes-related amputation in Barbados: a prospective case-control study. *Diabetes Care.* 2009;32:306-7.
55. Tentolouris N, Al-Sabbagh S, Walker MG, Boulton AJ, Jude EB. Mortality in diabetic and nondiabetic patients after amputations performed from 1990 to 1995: a 5-year follow-up study. *Diabetes Care.* 2004;27:1598-1604.
56. Heikkinen M, Saarinen J, Suominen VP, Virkkunen J, Salenius J. Lower limb amputations: differences between the genders and long-term survival. *Prosthet Orthot Int.* 2007;31:277-286.