



Papillary Carcinoma Arising in Struma Ovarii

Struma Ovariiden Kaynaklanan Papiller Karsinoma

Yavuz Yalçın, Türkan Mete*, Gültekin Ozan Küçük**, Aysu Başak Özbacı***, Nurcan Duman Salman****, Yusuf Aydın*****

Ordu Training and Research Hospital, Clinic of Endocrinology and Metabolism, Ordu, Turkey

*Samsun Training and Research Hospital, Clinic of Endocrinology and Metabolism, Samsun, Turkey

**Samsun Training and Research Hospital, Clinic of General Surgery, Samsun, Turkey

***Samsun Training and Research Hospital, Clinic of Radiology, Samsun, Turkey

****Ordu Training and Research Hospital, Clinic of Pathology, Ordu, Turkey

*****Düzce University Faculty of Medicine, Department of Endocrinology and Metabolism, Düzce, Turkey

Abstract

Struma ovarii, which is classified as benign or malignant, is a mature ovarian teratoma consisting mainly of the thyroid tissue. Here, we present the case of malign struma ovarii in a patient with right adnexal mass. In a 53-year-old female, who was referred to our hospital with pelvic pain, abdominopelvic imaging revealed a cystic lesion measuring 15x14 cm in diameter in the right adnexa. Total abdominal hysterectomy and bilateral salpingo-oophorectomy were performed. Microscopic evaluation revealed a 1.5x1x0.5 cm papillary carcinoma focus in frozen sections of the mural nodule which was observed inside the cyst. Following the surgical procedure, the patient's TSH levels were kept low by thyroxine treatment, and it was decided to follow the patient by annual measurement of thyroglobulin levels and pelvic imaging. There is not a common consensus on optimal treatment of malignant struma ovarii. Treatment options depend on cases or case series. *Turk Jem 2015; 19: 112-114*

Key words: Malignant struma ovarii, papillary thyroid carcinoma, ovarian teratoma

Özet

Struma ovarii esas olarak matür tiroid dokusundan oluşur. Benign veya malign olarak sınıflandırılır. Sağ adneksiyal kitle ile başvuran bir malign struma ovarii olgusunu sunmaktayız. Pelvik ağrı şikayeti ile hastanemize başvuran 53 yaşındaki kadın hastanın abdominopelvik görüntülemesi, sağ adneksiyal alanda 15x14 cm çapında kistik lezyonun varlığını göstermekteydi. Total abdominal histerektomi ve bilateral salpingo-ooferektomi yapıldı. Mikroskopik değerlendirmede, kist içinde gözlenen mural nodülde 1,5x1x0,5 cm papiller karsinoma odağı gözlemlendi. Cerrahiye takiben tiroksin tedavisi ile TSH düzeyi suprese edildi ve hastanın yıllık olarak pelvik görüntüleme ve tiroglobulin düzeyleri ile izlenmesine karar verildi. Malign struma ovariiinin optimal tedavisi hakkında ortak bir görüş yoktur. Tedavi seçenekleri vaka veya vaka serilerine dayanmaktadır. *Turk Jem 2015; 19: 112-114*

Anahtar kelimeler: Malign struma ovarii, papiller tiroid karsinomu, over teratomu

Introduction

Struma ovarii is a differentiated or monodermal teratoma, mainly consisting of mature thyroid tissue (1). It accounts for approximately 5% of all ovarian teratomas. The presence of thyroid tissue comprising more than 50% of the overall tissue is needed in order to define the mass as struma ovarii (2,3). The age of onset is 40-60 years. Clinically, it mainly presents as painful or painless mass, and less likely with ascites (4). It is classified as benign or malignant according to histological examination. Histological properties of thyroid cancer are seen in 5-37% of struma ovarii cases (3,4). Diagnostic criteria for malignant struma ovarii are similar to that for differentiated thyroid carcinoma. Diagnosis of

carcinoma is based on typical cytological features of papillary thyroid carcinoma, or for follicular carcinoma, on evidence of tumoral invasion, metastasis or recurrence (5).

Treatment of benign struma ovarii is surgical resection of ovarian tumor by unilateral oophorectomy. There is no common consensus on optimal treatment of women diagnosed with malignant struma ovarii. It is individually considered for each patient, whether total thyroidectomy and radioactive iodine treatment is necessary to be added to optimal surgical procedure (unilateral or bilateral salpingo-oophorectomy with/without hysterectomy). Treatment options are based on case series (6,7,8).

In this paper, we present a patient who had pelvic pain and underwent total abdominal hysterectomy and bilateral salpingo-

oophorectomy after detection of right adnexal mass and, pathological examination revealed struma ovarii.

Case Report

A 53-year-old female patient was, referred to our gynecology clinic in March 2013 with the complaint of pelvic pain. Physical examination revealed a palpable mass in the right lower quadrant of the abdomen. Pelvic ultrasound (US) showed a cystic lesion with a diameter of 15 cm in the right adnexa and hypodense areas in the uterus with a maximum size of 2 cm. Abdominal and pelvic computed tomography (CT) revealed a cystic lesion in fluid density measuring of 15x14 cm in diameter (ovarian cyst), and hypodense areas in the uterus with the largest one measuring 23 mm in diameter in the uterine corpus (uterine myoma) (Figure 1). Total abdominal hysterectomy and bilateral salpingo-oophorectomy (TAH/BSO) were performed for diagnosis and treatment. Macroscopic examination revealed a cyst with a smooth inner surface measuring 17x14x10 cm in diameter, filled with a yellow-brown fluid. There was a mural nodule measuring 3x2.5x1.5 cm inside the cyst. Microscopic examination revealed mature thyroid tissue consisting of micro and macrofollicles in sections of the mural nodule. A papillary carcinoma focus of 1.5x1x0.5 cm was observed in this area. Lymphovascular invasion, capsule invasion or capsule rupture was not observed. There was no extraovarian spread (Figure 2). In addition, microscopic evaluation of the two solid nodules in myometrium with the larger one 1.5x1.3x1 cm in size, were compatible with uterine myomas. Laboratory tests of the patient with the diagnosis of papillary carcinoma arising in struma ovarii revealed subclinical hypothyroidism. Anti-TPO and anti-Tg were negative. Thyroid US was consistent with thyroiditis; no solid or cystic lesions were observed.

Since there was no extraovarian spread, distant metastasis or coexistence of thyroid cancer, prophylactic thyroidectomy

or radioactive iodine treatment was not planned. TSH levels were kept low with levothyroxine treatment and the patient was followed up with periodical evaluations with yearly serum thyroglobulin evaluation and pelvic imaging.

Discussion

Histological examination of thyroid components in malignant struma ovarii generally reveals papillary thyroid carcinoma, and less often, follicular carcinoma (3,4). In a study evaluating 54 struma ovarii patients, carcinoma was detected in 13 patients (24%). Eleven of the patients had papillary carcinoma where two of them were reported to have follicular carcinoma (9). Cancer is more frequently seen in larger tumors (75% of carcinoma detected tumors were larger than 16 cm), carcinoma is rarely seen in tumors smaller than 5 cm (10). Similarly, tumor size in our case was 17 cm and a classical variant papillary carcinoma focus was detected. There is not a common consensus on optimal treatment of malignant struma ovarii. It is not known whether total thyroidectomy and radioactive iodine treatment is needed in addition to optimal surgical procedure (unilateral or bilateral salpingo-oophorectomy with/without hysterectomy). Treatment options depend on cases or case series (6,7,8). Decision of thyroidectomy and radioactive iodine treatment is based upon the extent of ovarian disease and existence of metastasis. Thyroidectomy followed by radioactive iodine treatment is recommended for large tumors (>4 cm) with distant metastasis or extraovarian spread, existence of BRAF mutation or synchronized thyroid cancer. Thyroxine treatment is also necessary for these patients. In women with a low recurrence risk (with no extraovarian spread or distant metastasis), TSH must be kept equal to or a little under the minimal normal levels and they must be evaluated with annual measurements of thyroglobulin levels (3,11,12).

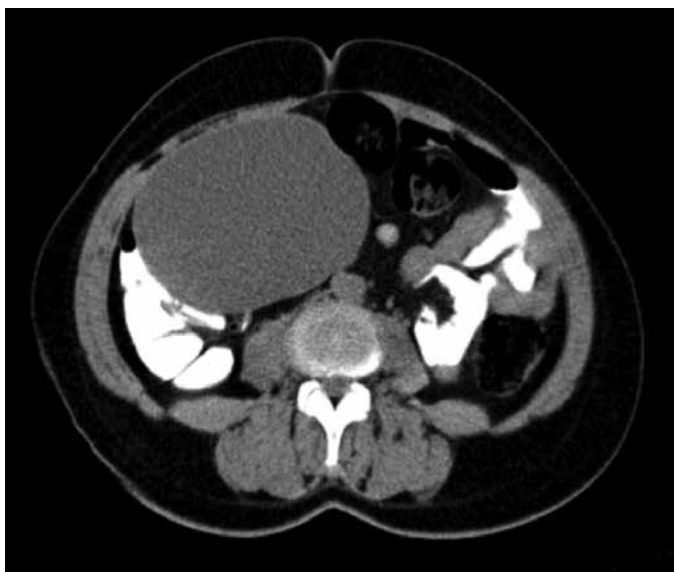

Figure 1. Axial CT images before IV contrast demonstrate the homogeneous giant cystic mass which take origin from the right adnexa

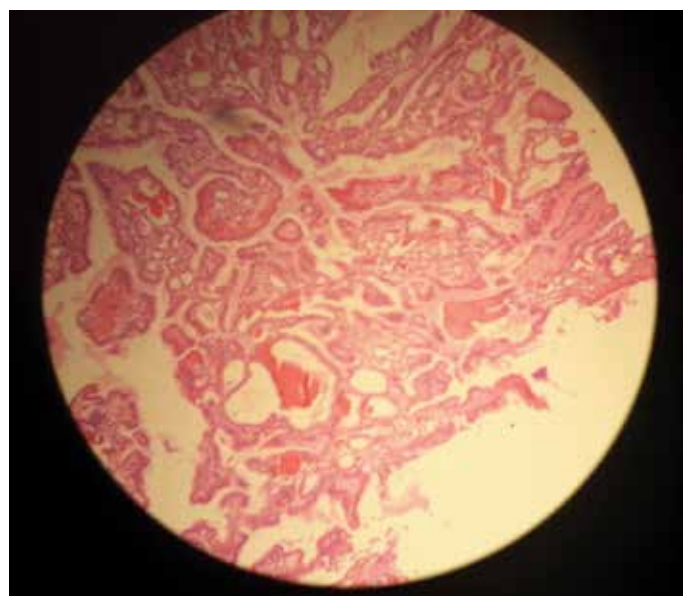


Figure 2. Microscopic examination of hematoxylin and eosin (H&E) stained sections. 53-year-old female patient with an ovarian lesion containing thyroid follicles and foci of papillary carcinoma, most probably representing a papillary carcinoma arising in a struma ovarii

In the treatment of metastatic struma ovarii cases, total thyroidectomy must be performed after oophorectomy and before radioactive iodine treatment. In a review of 24 cases with struma ovarii, recurrence was not observed in 4 patients who underwent adjuvant thyroidectomy and radioactive iodine treatment. Recurrence was observed in 8 patients who had been on conservative follow-up (clinical follow-up with thyroglobulin levels) after ovarian surgery. Seven out of 8 patients with recurrence were treated with thyroidectomy and radioactive iodine treatment. One patient, who did not receive additional treatment after first recurrence, died 6 months after recurrence (11).

In another case series, 4 patients with struma ovarii were reviewed. No distant metastasis or extraovarian spread of tumor was observed. Surgical procedure was unilateral (1 patient) and bilateral salpingo-oophorectomy (1 patient) in two patients; total abdominal hysterectomy and bilateral salpingo-oophorectomy in two patients. Only one patient underwent thyroidectomy and radioactive iodine treatment. This patient was found to have synchronised papillary thyroid cancer. No disease recurrence was observed in any patients in a mean follow-up of 9 years (13).

In our case, the papillary carcinoma arising from struma ovarii had a size of 1.5x1x0.5 cm, there was no extraovarian spread, synchronized thyroid cancer or distant metastasis. For this reason, conservative follow-up of the patient after surgical procedure was decided. The patient's TSH levels were kept minimal with thyroxin treatment and she was decided to be followed with yearly serum thyroglobulin evaluation and pelvic imaging.

In summary, struma ovarii is a rare entity that may be considered when there are findings of an ovarian mass. As evidenced in this case report, it is important to remember that a minority of struma ovarii are associated with thyroid carcinoma and this may significantly alter patient management.

Concept: Yavuz Yalçın, Türkan Mete, **Design:** Yavuz Yalçın, Türkan Mete, **Data Collection or Processing:** Yavuz Yalçın, Türkan Mete,

Aysu Başak Özbalcı, Nurcan Salman Duman, **Analysis or Interpretation:** Yavuz Yalçın, Türkan Mete, Yusuf Aydın, **Literature Search:** Türkan Mete, Gültekin Ozan Küçük, **Writing:** Türkan Mete, **Peer-review:** Externally peer-reviewed, **Conflict of Interest:** No conflict of interest was declared by the authors, **Financial Disclosure:** The authors declared that this study has received no financial support.

References

1. Duzendorfer T, delas Morenas A, Kalir T, Levin RM. Struma ovarii and hyperthyroidism. *Thyroid* 1999;9:499-502.
2. Kondi-Pafiti AI, Mavriannaki P, Grigoriadis Ch, Kontogianni-Katsarou K, Mellou A, Kleanthis CK, Liapis A. Monodermal teratomas (struma ovarii). Clinicopathological characteristics of 11 cases and literature review. *Eur J Gynaecol Oncol* 2011;32:657-669.
3. Yassa L, Sadow P, Marqusee E. Malignant struma ovarii. *Nat Clin Pract Endocrinol Metab* 2008;4:469-472.
4. Yoo SC, Chang KH, Lyu MO, Chang SJ, Ryu HS, Kim HS. Clinical characteristics of struma ovarii. *J Gynecol Oncol* 2008;19:135-138.
5. Young RH. New and unusual aspects of ovarian germ cell tumors. *Am J Surg Pathol* 1993;17:1210-1224.
6. Gunasekaran S, Kopecka E, Maung KH, England RJ. Struma ovarii and the thyroid surgeon. *J Laryngol Otol* 2012;126:858-860.
7. Billan S, Abdah-Bortnyak R, Cohen H, Bar-Shalom R, Guilburd J, Michael K, Kuten A, Ben Arush MW. Metastatic malignant struma ovarii. *Isr Med Assoc J* 2011;13:247-248.
8. Michels A, Haugen B. Malignant struma ovarii. *J Clin Endocrinol Metab* 2010;95:1505.
9. Devaney K, Snyder R, Norris HJ, Tavassoli FA. Proliferative and histologically malignant struma ovarii: a clinicopathologic study of 54 cases. *Int J Gynecol Pathol* 1993;12:333-343.
10. Young RH. New and unusual aspects of ovarian germ cell tumors. *Am J Surg Pathol* 1993;17:1210-1224.
11. DeSimone CP, Lele SM, Modesitt SC. Malignant struma ovarii: a case report and analysis of cases reported in the literature with focus on survival and 131I therapy. *Gynecol Oncol* 2003;89:543-548.
12. Willemse PH, Oosterhuis JW, Aalders JG, Piers DA, Sleijfer DT, Vermey A, Doorenbos H. Malignant struma ovarii treated by ovariectomy, thyroidectomy, and 131I administration. *Cancer* 1987;60:178-182.
13. Marti JL, Clark VE, Harper H, Chhieng DC, Sosa JA, Roman SA. Optimal surgical management of well-differentiated thyroid cancer arising in struma ovarii: a series of 4 patients and a review of 53 reported cases. *Thyroid* 2012;22:400-406.