



A Case of Giant Prolactinoma Presented as a Nasopharyngeal Mass

Nazofarenks Kitlesi Olarak Prezente Olan Dev Bir Prolaktinoma Olgusu

Alev Selek, Berrin Çetinarslan, Zeynep Cantürk, İlhan Tarkun, Özlem Akyay

Kocaeli University Faculty of Medicine, Department of Endocrinology and Metabolism, Kocaeli, Turkey

Abstract

Giant prolactinomas may present with atypical tumor mass effects, as they are characterized by massive extrasellar invasion. Nasopharyngeal involvement of prolactinoma is a rare condition and it has been described in some case reports in the literature. Medical management of prolactinomas with dopamine agonist drugs has been widely recommended as the first choice of treatment as it is very effective in decreasing both tumor size and prolactin levels. Some acute complications, such as brain and optic chiasmal herniations, pneumocephalus and cerebrospinal fluid leakage during Cabergoline treatment have been reported. In order to avoid these life-threatening complications, Cabergolin dose should be titrated gradually and the patient should be evaluated closely, also with imaging studies in case of necessity. Here, we report a 19-year-old male patient with giant prolactinoma who presented with nasal obstructive symptoms and was diagnosed by nasopharyngeal biopsy. He was treated with Cabergoline successfully without any complication. *Turk Jem 2014; 18: 103-105*

Key words: Giant prolactinoma, nasopharyngeal mass, pituitary adenoma

Özet

Dev prolaktinomalar masif ekstrasellar bölge yayılımı nedeni ile dev prolaktinoma atipik kitle etkisi ile başvurabilir. Prolaktinomanın nazofarenks tutulumu çok nadirdir ve literatürde az sayıda bildirim mevcuttur. Prolaktinoma tedavisinde tümör boyutu ve prolaktin düzeylerini etkin biçimde düşüren dopamin agonistleri ilk tedavi seçeneği olarak önerilmektedir. Cabergolin tedavisi altında beyin ve optik kiazm herniasyonu, pnömosefali ve serebrospinal sıvı kaçağı gibi akut komplikasyon gelişen olgu sunumları mevcuttur. Hayati tehlikesi olan bu komplikasyonları önlemek için cabergolin tedavisi kademeli olarak başlanmalı ve hasta gerektiğinde görüntüleme de yapılarak yakın takip edilmelidir. Burada, burun tıkanıklığı belirtileri ile başvuran ve nazofarenks biyopsisi ile tanı konulan 19 yaşında bir erkek dev prolaktinoma olgusu sunuldu. Hasta, cabergolin tedavisi ile başarılı ve komplikasyonsuz tedavi edildi. *Turk Jem 2014; 18: 103-105*

Anahtar kelimeler: Dev prolaktinoma, nazofarenks kitlesi, hipofiz adenomu

Introduction

Prolactinomas are the most frequently encountered secretory pituitary tumors with an annual incidence of 30 per 100.000 persons (1). Giant prolactinoma is characterized by large size (>40 mm in diameter) and massive extrasellar invasion (2). Majority of patients with giant prolactinoma have symptoms or signs of hypopituitarism, especially hypogonadism, but they usually present with tumor mass effects such as headache and visual disturbance. Although less frequently, seizures, hydrocephalus and unilateral exophthalmos may also be seen. Nasopharyngeal involvement of prolactinoma has been described only in few cases in the literature as it is an extremely rare condition (3,4).

Treatment of prolactinoma aims at reversing the symptoms dependent on hormone hypersecretion and the neurological and visual manifestations due to tumor-mass effect. The ideal treatment must prevent or even improve other pituitary

dysfunctions, if present. Medical management of prolactinoma with dopamine agonist drugs has been widely recommended as the treatment of choice. In case of emergency situations, such as apoplexy and drug resistance or intolerance, surgery should be chosen. As these tumors are largely invasive, endoscopic techniques are more favourable in defining especially cavernous sinus invasion (5).

Here, we report the case of a patient with giant prolactinoma who presented with epistaxis, rhinorrhea and unilateral exophthalmos with nasopharyngeal extension and treated with cabergoline.

Case Report

A 19-year-old male patient, who had the complaints of nasal obstruction, rhinorrhea and epistaxis for two years, was diagnosed with prolactinoma via nasopharyngeal mass biopsy by an ENT physician. The biopsy reflected diffusely prolactin

stained neuroendocrine tumor with Ki 67 index of 10%. He had no sexual dysfunction or any other symptoms of pituitary hormone deficiencies. On physical examination, all systems were normal including genital examination, except for unilateral exophthalmos of the right eye. There were bitemporal quadrantanopia on initial visual field examination. Liver and renal function tests were all within normal range and hormonal profile was as follows: prolactin: 10450 $\mu\text{g/l}$ (1/100 diluted), FSH:2.3 IU/l, LH:2.2 IU/l, total testosterone:380 ng/dl TSH:2.9 mU/L, sT4:1.17 ng/dl, GH:<0.05 $\mu\text{g/l}$ IGF-1:181 (normal range:146-415), morning basal cortisol:18 $\mu\text{g/l}$ and cortisol after 1 mg dexamethasone suppression: 0.8 $\mu\text{g/l}$. Gadolinium-enhanced magnetic resonance imaging (MRI) of the hypothalamic-pituitary region revealed a 7 cm pituitary macroadenoma extending to the nasopharynx and temporal lobe with compression of optic chiasm, cavernous and sphenoid sinus invasion. There was also bony erosion of the clivus. The patient was started on Cabergoline at a dosage of 0.5 mg per week, which was increased gradually; at the end of 3 months

he was receiving 2 mg every week. Even with a single dose of 0.25 mg Cabergoline, his prolactin level decreased to 580 $\mu\text{g/l}$ and at the end of the first week, visual field examination was repeated and it was nearly normal (Figure 1). After six months of treatment with Cabergoline 2 mg/week, prolactin level was 80 $\mu\text{g/l}$, then drug dose was increased up to 3 mg per week. Visual field examination was completely normal and the diameter of the tumor decreased to 4 cm and decompression of the optic chiasm was achieved on control cranial MRI (Figure 2). He was completely asymptomatic besides slightly increased rhinorrhea, unilateral exophthalmos and decreased nasal obstruction. He is still on follow-up.

Discussion

Prolactinomas are known to be larger and more invasive in men and to show histologic evidence of more rapid growth (6). Giant prolactinomas usually present with the symptoms of mass effect due to invasion of the vital structures around the pituitary gland, such as headache, visual disturbance, seizures and less frequently hydrocephalus, exophthalmos, nasal obstruction, epistaxis, and craniocervical junction instability (3,4,7). The current case had presented with epistaxis and nasal obstruction and was diagnosed by nasopharyngeal biopsy of the tumor. Although majority of the patients with giant adenoma have pituitary hormone deficiencies, especially hypogonadism, there was no additional pituitary hormonal disturbance in our patient.

The tumor was highly invasive to the adjacent structures on MRI and there were quadrantanopia in visual field examination. As complete surgical removal of the adenoma was not possible and all other pituitary functions were intact, medical treatment with Cabergoline was used as a first-line treatment. Even with a single dose of 0.25 mg of Cabergoline, prolactin level decreased nearly 20-fold and at the end of the first week, visual field examination was nearly normal as described in some cases in the literature (8). Also in a recent study about Cabergoline as first-line treatment for invasive prolactinoma, 97% reduction of tumor size and serum prolactin levels were reported with at least 12 months of Cabergoline treatment (9).

Some acute complications, such as brain and optic chiasm herniations, pneumocephalus and cerebrospinal fluid leakage,

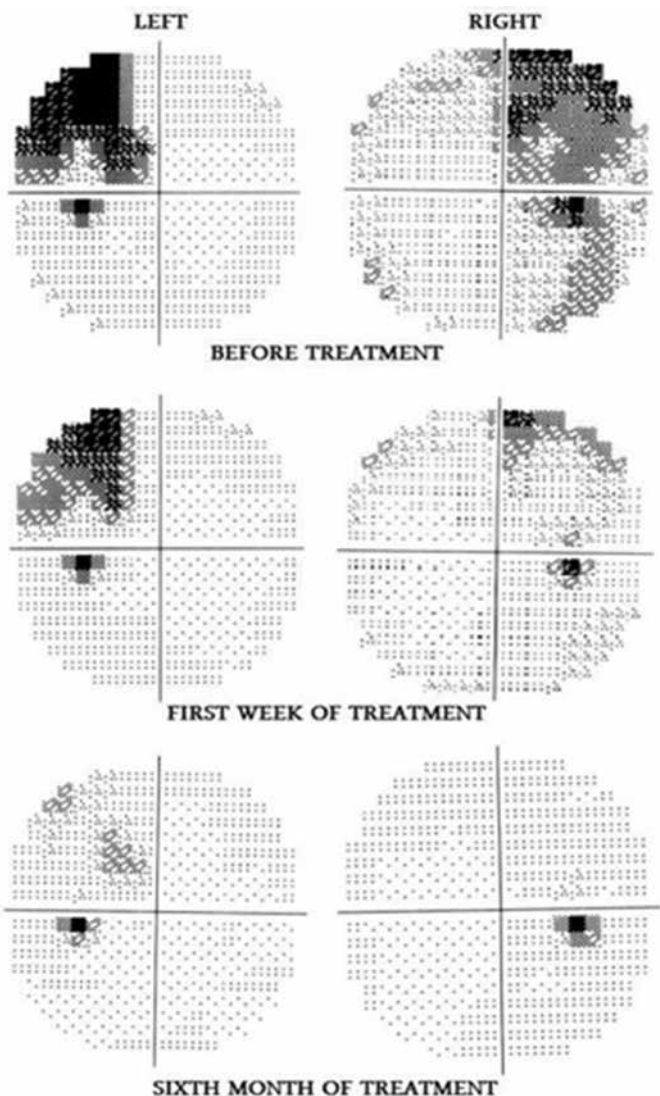


Figure 1. Visual field examinations of the patient before, at first week and at sixth month of treatment

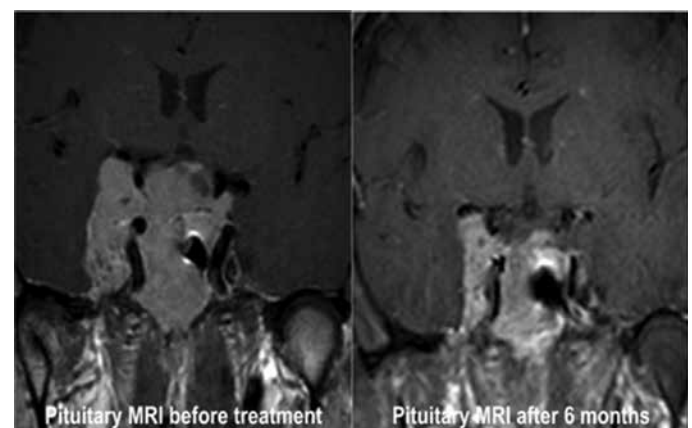


Figure 2. Magnetic Resonance imaging of pituitary gland adenoma of the patient, before and 6 months after treatment

during Cabergoline treatment of giant prolactinoma have been described in case reports (10,11). In order to avoid these life-threatening complications, we started Cabergolin treatment at a dose of 0.5 mg per week and increased gradually with close monitoring and MRI follow-up. There were not any complication during the 6-mount period of follow-up except for slightly increased rhinorrhea which was already present before the treatment. Raverot et al. have reported that chiasmal herniation may be seen even 4 years after Cabergolin treatment initiation, therefore, close follow-up with MRI and visual field examination should be considered (12).

Malignant prolactinoma is an extremely rare entity and none of the histological findings may distinguish pituitary adenoma from carcinoma. Only demonstration of metastatic spread to remote areas of the central nervous system or outside, can make the diagnosis of pituitary carcinoma. In our case, although the biopsy revealed a benign tumor, malignant prolactinoma and metastasis should always be kept in mind during follow-up, because of the invasive character and high Ki 67 levels of the tumor.

After 6 mounts of treatment with Cabergoline with a final dose of 3 mg per week, visual field examination was completely normal and pituitary MRI showed markedly decreased tumor size to 4 cm in diameter. He was asymptomatic except for rhinorrhea in the morning. Unilateral exophthalmos and nasal obstruction regressed.

Conclusion

In the light of this case, we conclude that giant prolactinoma may present with uncommon symptoms and should be kept in mind in the differential diagnosis of nasopharyngeal masses. If urgent decompression is not needed, Cabergoline should be chosen for the treatment as it is very effective in reducing both tumor size and prolactin levels. Rapid shrinkage of the tumor may cause some

life-threatening complications, therefore, Cabergolin should be started at small doses and titrated gradually. In addition, a close follow-up including imaging studies should be performed.

Conflicts of Interest

There are no conflicts of interest.

References

1. Fernandez A, Karavitaki N, Wass JA. Prevalence of pituitary adenomas: A community-based, cross-sectional study in Banbury (Oxfordshire, UK). *Clin Endocrinol (Oxf)* 2010;72:377-382.
2. Shrivastava RK, Arginteanu MS, King WA, Post KD. Giant prolactinomas: Clinical management and long-term follow up. *J Neurosurg* 2002;97:299-306.
3. Chaurasia PK, Singh D, Meher S, Saran RK, Singh H. Epistaxis as first clinical presentation in a child with giant prolactinoma: Case report and review of literature *J Pediatr Neurosci* 2011;6:134-137.
4. Godey B, Morandi X, Le Gall F, Feat S, Brassier G, Le Clech G. Pituitary adenomas with infra-sellar extension into the nasopharynx. *J Laryngol Otol* 1999;113:1109-1111.
5. Ceylan SI, Anik I, Koc K. A new endoscopic surgical classification and invasion criteria for pituitary adenomas involving the cavernous sinus. *Turk Neurosurg* 2011;21:330-339.
6. Delgrange E, Trouillas J, Maiter D, Donckier J, Touniaire J. Sex-related difference in the growth of prolactinomas: a clinical and proliferation marker study *J Clin Endocrinol Metab* 1997;82:2102-2107.
7. Zaben MJ, Harrison SE, Mathad NV. Giant prolactinoma causing cranio-cervical junction instability: a case report. *Br J Neurosurg* 2011;25:754-756.
8. Dash S, Annamalai AK, Simpson HL, Sarkies N, Antoun NM, Mannion R. Acute shrinkage of a giant prolactinoma, masquerading as an erosive skull base tumour, with cabergoline. *QJM* 2013;106:85. [Epub ahead of print].
9. Cho EH, Lee SA, Chung JY, Koh EH, Cho YH, Kim JH, Kim CJ, Kim MS. Efficacy and safety of cabergoline as first line treatment for invasive giant prolactinoma. *J Korean Med Sci* 2009;24:874-878.
10. Dhanwal DK, Sharma AK. Brain and optic chiasmal herniations into sella after cabergoline therapy of giant prolactinoma. *Pituitary* 2011;14:384-387.
11. Machicado JD, Varghese JM, Orlander PR. Cabergoline-Induced pneumocephalus in a medically treated macroprolactinoma. *J Clin Endocrinol Metab* 2012;97:3412-3413. [Epub ahead of print].
12. Raverot G, Jacob M, Jouanneau E, Delemer B, Vighetto A, Pugeat M, Borson-Chazot F. Secondary deterioration of visual field during Cabergoline treatment for macroprolactinoma. *Clin Endocrinol* 2009;70:588-592.