

# Induction of an Autoimmune Thyroid Disease with Nickel Chloride in Brown Norway Rats

## *Kahverengi Norveç Sıçanlarında Nikel Klorid ile Otoimmün Tiroid Hastalığının İndüklenmesi*

Sultan Al-Mogairen

King Saud University, Medicine, Riyadh, Saudi Arabia

### Abstract

**Objective:** Hazards caused by nickel exposure, due to its direct and autoimmune reaction, are a growing problem. The aim of this study is to explore whether nickel will induce autoimmune thyroid disease in immunosensitive rats.

**Materials and Methods:** In this study, twelve Brown Norway rats were selected from our previous study (Almogairen et al, Lupus 2009 April). The rats were sacrificed after the exposure to nickel and then thyroidectomized. Histological studies of the thyroid were performed in the group of six rats positively responding to nickel and were compared with the equal number of rats in the autoantibody-negative control group.

**Results:** Histologically, epithelial follicular proliferation in the thyroid gland was significant in the subcutaneous nickel group ( $p=0.05$ ).

**Conclusions:** When correlating the above results with serum ANA response of the same rats, it might be concluded that nickel chloride might induce autoimmune thyroid disease in immunosensitive rats. *Türk Jem 2009; 13: 71-4*

**Key words:** Autoimmune, thyroid, ANA, nickel

### Özet

**Amaç:** Nikele maruz kalmanın getirdiği tehlikeler, direkt ve otoimmün reaksiyon nedeniyle, büyümekte olan bir problemdir. Bu çalışmanın amacı, nikelin otoimmün tiroid hastalığını başlatıp başlatmadığını araştırmaktır.

**Gereç ve Yöntemler:** Bu çalışmada, daha önceki çalışmamızdan (Almogairen at al., Lupus, 2009 Nisan) 12 kahverengi Norveç sıçanı seçildi. Sıçanlar nikel maruz bırakıldıktan sonra öldürüldü ve tiroidektomize edildi. Nikele pozitif cevap veren gruptaki 6 sıçan üzerinde histolojik incelemeler yapıldı ve aynı sayıdaki antikor negatif kontrol grubu sıçanları ile karşılaştırıldı.

**Bulgular:** Histolojik olarak, subkutan nikel uygulanan grubun tiroid bezinde epitelyal folliküler proliferasyon anlamlıydı.

**Sonuç:** Yukarıdaki sonuçlar, aynı sıçanların serum antinükleer antikor (ANA) cevabı ile ilişkilendirildiğinde, nikel klorürün immüno sensitif sıçanlarda otoimmün tiroid hastalığının indüklenmesinde önemli rol oynayabileceği sonucuna varılabilir. *Türk Jem 2009; 13: 71-4*

**Anahtar kelimeler:** Otoimmün, tiroid, ANA, nikel

### Introduction

Nickel allergy is the most common cause of allergic contact dermatitis. It's prevalence in the general population is about 7-10% with predominance in females (female: male ratio of 7-14:1) (1).

Nickel is used for making stainless steel which is used for production of equipments, fashion jewelry, coins, metal eyeglasses, prosthetic implants, as well as dental crown, bridges and implants (1-6).

One of the target organs to toxins and drugs is the thyroid gland, which dysfunction is manifested as hypothyroidism, hyperthyroidism, c-cell hyperplasia (7,8). Thyroid diseases are associated with drugs such as interferon-alpha, interleukin-2, lithium, cyclosporine and amiodarone, or toxins such as organochlorine (9-16).

Chronic interferon-alpha exposure leads to changes in thyroid gland, including enlarged follicles lined by thickened granular and

oxyphilic thyrocytes with diffuse mononuclear infiltrates of the stroma (8). Organochlorine induces thyroid gland cysts and c-cell hyperplasia (7).

The objective of this experimental study is to demonstrate whether nickel would induce autoimmune thyroid disease in Brown Norway rats. This study is an extension of our previous study (Almogairen et al, Lupus 2009 April) 17, but examining the correlation between the autoimmune response and the histopathological changes in the thyroid gland.

## Materials and Methods

Brown Norway rats (BN) were purchased from Charles Rivers Laboratories, Wilmington, U.S.A. They were kept in polycarbonate metrolon plastic cages covered with stainless steel cover in the animal house in the College of Medicine, King Saud University, Riyadh, Saudi Arabia. They were maintained under 12-hr dark: 12-hr light cycles and were kept under observation for three weeks. No evidence of sickness was observed. All rats were 8-11 weeks old at the onset of the experiment. There were a total number of twelve rats with an average weight of 157 g. There were four groups: the first and the second groups (six rats) were called subcutaneous nickel group (three rats) and oral nickel group (three rats). The third and the fourth groups (six rats) were called subcutaneous normal saline control group (three rats) and oral normal saline control group (three rats).

All the above groups were selected for thyroid histological studies from our previous study, where the first and the second nickel groups were autoantibody-positive for serum ANA, anti-dsDNA, anti-Smith, anti-SSA and anti-SSB. On the other hand, the third and the fourth control normal saline groups were overall autoantibody-negative. The above selected groups were sacrificed after fourteen weeks of exposure to nickel chloride or normal saline and then thyroidectomized. The tissues taken from them were bisected and fixed in 10% buffered formalin for 24 hours. The tissues were then processed in the Tissue-Tek vacuum infiltration processor and stained using hematoxylin and eosin stain. The slides were examined blindly by histopathologist using light microscope.

## Results

The maximum serum antibody titers in the selected rats from our previous study are shown in Table 1.

The histopathological results are shown in Table 2. The changes in the thyroid gland were accepted as negative if all of the parameters shown in Table 2 were negative, otherwise, positive. Positive changes in the thyroid gland depicted in Figure 1 were observed in 3/3 ( $p=0.05$ ) of subcutaneous nickel chloride group, on the other hand,  $p$  value was 0.49 in the oral nickel group.

## Discussion

There are a limited number of publications concerning the structure of thyroid gland following the exposure to some drugs and toxins (7,10,12-14). To our knowledge, this is the first experimental animal study showing the correlation between the histopathological changes in the thyroid gland secondary to challenge with nickel and the serum autoimmune response. One study showed that in rats, injection of nickel sulfate (NISO4) induced the epithelial proliferation in the thyroid glands (16).

In our previous study, almost all serum autoantibodies in Brown Norway rats were undetectable prior to intervention. After challenge with nickel chloride, serum ANA appeared early and in a significant number of rats ( $p<0.05$ ) in both subcutaneous and orally treated rats. The same response ( $p<0.05$ ) was seen with anti-SSA in the subcutaneous nickel chloride group. Other serum autoantibodies including anti-dsDNA, anti-Smith and anti-SSB were insignificant (17). The main histopathological finding of the present study was increased epithelial follicular proliferation in the subcutaneous nickel group ( $p=0.05$ ). In the oral nickel group, increased epithelial follicular changes were observed only in one rat, which was probably due to the processing of nickel chloride substance by gastrointestinal M-cells (18).

The mechanism causing these effects could be due to direct toxic injury, autoimmunity or due to disruption of the hypothalamic-pituitary-thyroid (HPT) axis, a disturbance in the calcium homeostasis or in the energy metabolism (7).

Table 1. Maximum serum antibody titres of the rats in which histopathology was performed

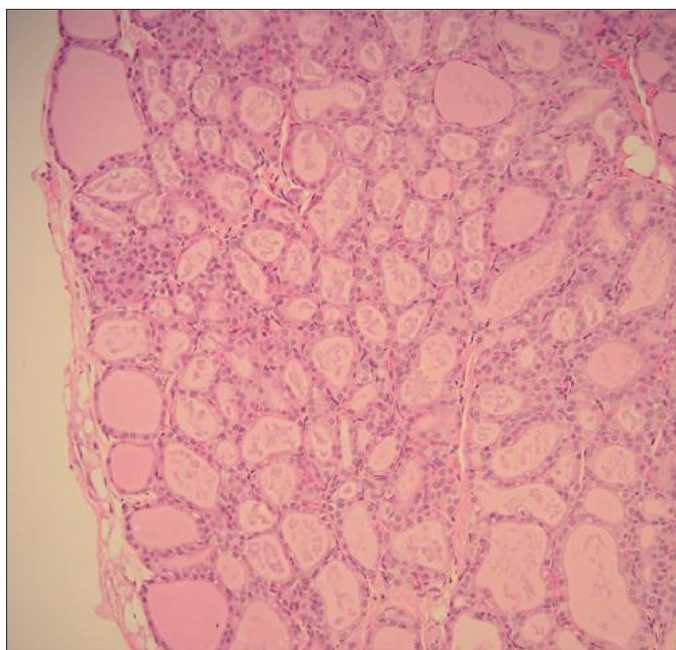
RATS	ANA ( $\leq 1/10$ ) significant	Anti-dsDNA ( $\geq 0.08$ ) significant	Anti-Smith ( $\geq 0.06$ ) significant	Anti-SSA ( $\geq 0.12$ ) significant	Anti-SSB ( $\geq 0.05$ ) significant
Nickel SC1	1/20	0.088	-ve	0.274	0.09
Nickel SC2	1/80	0.080	0.122	0.14	-ve
Nickel SC3	1/80	0.194	0.147	-ve	-ve
Nickel PO1	1/160	0.211	0.109	0.253	-ve
Nickel PO2	1/20	0.231	0.23	0.17	0.204
Nickel PO3	1/80	0.231	0.149	1.8	0.16
Control SC1	-ve	-ve	0.06	-ve	-ve
Control SC2	-ve	-ve	-ve	-ve	-ve
Control SC3	-ve	-ve	-ve	-ve	-ve
Control PO1	-ve	-ve	-ve	-ve	-ve
Control PO2	-ve	0.88	-ve	-ve	-ve
Control PO3	-ve	-ve	-ve	-ve	-ve

SC: Subcutaneous  
PO: Per oral  
-ve: Negative

Table 2. Histopathological features of silicate-tested&amp;control groups

Thyroid of the following rast	Inflammation	Autoimmune thyroiditis	Granuloma	Epithelial follicular proliferation	Hurthle cell change	Neoplastic change	Fibrosis atrophy
Nickel SC1	-ve	-ve	-ve	++	-ve	-ve	-ve
Nickel SC2	-ve	-ve	-ve	+	-ve	-ve	-ve
Nickel SC3	-ve	-ve	-ve	++	-ve	-ve	-ve
Nickel PO1	-ve	-ve	-ve	-ve	-ve	-ve	-ve
Nickel PO2	-ve	-ve	-ve	-ve	-ve	-ve	-ve
Nickel PO3	-ve	-ve	-ve	+	-ve	-ve	-ve
Control SC1	-ve	-ve	-ve	-ve	-ve	-ve	-ve
Control SC2	-ve	-ve	-ve	-ve	-ve	-ve	-ve
Control SC3	-ve	-ve	-ve	-ve	-ve	-ve	-ve
Control PO1	-ve	-ve	-ve	-ve	-ve	-ve	-ve
Control PO2	-ve	-ve	-ve	+	-ve	-ve	-ve
Control PO3	-ve	-ve	-ve	+	-ve	-ve	-ve

-ve= 0= negative  
 += 1= mild  
 ++= 2= moderate  
 +++= 3= severe  
 SC: subcutaneous  
 PO: per oral



**Figure 1.** Rat thyroid, hematoxylin and eosin stain (x200 magnification). Sections show histology of thyroid gland. There is mild proliferation of the thyroid follicles. The follicles are smaller in size, the amount of colloid is diminished and are lined by plump cuboidal epithelium.

With the above significant response of Serum ANA and anti-SSA, the autoimmunity is probably playing a role in the epithelial follicular proliferation in the thyroid gland.

In conclusion, the findings from this study indicate that nickel chloride might induce autoimmune thyroid disease and we recommend, in the future, a immunohistochemical tissue study to be conducted on murine antithyroid antibodies, if available.

### Acknowledgement

The study was supported by a grant from Research Center, College of Medicine, King Saud University. The author is grateful to Dr. Sufia Husain, FRC Path for reporting histology. The author is also grateful for the following: Dr. B. Al-Mohaimeed, Dr. N. Khalil, Mr. M. Marzook, and Mr. S. Abu-al-Ghaith, S. Seno, Mitzi Guinto, Joann Octubre for their cooperation, and the Research Ethic Committee, College of Medicine for the approval of this study.

### References

1. D'Ambrosio FP, Bagnato GF, Guarneri B, et al. The role of nickel in foods exacerbating nickel contact dermatitis. *Allergy* 1998; 53: 143-145.
2. Sharma AD. Relationship between nickel allergy and diet. *Indian J Dermatol Venereol Leprol* 2007; 73: 307-312.
3. Cracchiolo A 3rd, Revell P. Metal concentration in synovial fluids of patients with prosthetic knee arthroplasty. *Clin Orthop Relat Res* 1982; (170):169-174.
4. Corazza M, Maranini C, Aleotti A, Virgili A. Nickel contact dermatitis due to the needle of an infusion pump, confirmed by microanalysis. *Contact Dermatitis* 1998; 39: 144.
5. Sterzl I, Prochazkova J, Hrdá P, Bartova J, Matucha Petr, Stejskal V. Mercury and nickel allergy: risk factors in fatigue and autoimmunity. *Neuroendocrinology Letters* 1999; 20: 221-228.
6. Strauss FG, Eggleston DW. IgA nephropathy associated with dental nickel alloy sensitization. *Am J Nephrol* 1985; 5: 395-397.
7. Sonne C, Wolers H, Leifsson PS, Iburg T, Jenssen BM, Fuglei E, et al. Chronic dietary exposure to environmental organochlorine contaminants induces thyroid gland lesions in Arctic foxes (*Vulpes lagopus*). *Environ Res* 2009; 109: 702-711.
8. Bullock KAC, Woodson EMH, Tao H, Boerner SA, Smolkin M, Grosh WW, et al. Autoimmune Toxicities associated with the administration of anti-Tumor vaccines and low-dose Interleukin-2. *J Immunother* 2005; 28: 412-419.
9. Axelstad M, Hansen PR, Boberg J, Bonnichen M, Nellermann C, Lund SP, Hougaard KS, Hass U. Developmental neurotoxicity of Propylthiouracil (PTU) in rats: Relationship between transient hypothyroxinemia during development and long-lasting behavioural and functional changes. *Toxico Applied Pharmacol* 2008; 232: 1-13.

10. Nakasawa T, Murata S, Kondo T, Nakamura N, Yamane T, Iwasa S & Kato R. Histopathology of the thyroid in amiodaron-induced hypothyroidism. *Patho Intern'l* 2008; 58: 55-58.
11. Nakamura R, Teshima R, Hachisuka A, Sato Y, Takagi K, Nakamura R, Woo GH, Shibutani M, Sawada JI. Effects of development hypothyroidism induced by maternal administration of methimazole or propylthiouracil on the immune system of rats. *Intern'l Immunopharma* 2007; 7: 1630-1638.
12. Zbucki RL, Winnicka M, Sawicki B, Szynaka B, Andzejewska A, Puchi Z. Alteration of parafollicular & cells activity in the experimental model of hypothyroidism in rats. *Folia Histochem et Cytobiologica* 2007; 45: 115-121.
13. Kimura H, Kimura M, Westra WH, Rose NR, Caturegli P. Increased thyroid fat and goitrous hypothyroidism induced by Interferon-Alpha. *Int J Exp* 2005; 86: 97-106.
14. Chen K, Wei Y, Sharp GC & Braley-Mullen H. Induction of experimental autoimmune thyroiditis in IL-12-/- mice. *The J Immuno* 2001; 167: 1720-1727.
15. Hassman RA, Dieguez C, Rennie DP, Weetman AP, Hall R & McGregor AM. The influence of cyclosporine A on the induction of experimental autoimmune thyroid disease in the PVG/c rat. *Clin Exp Immunol* 1985; 59: 10-16.
16. Cheng W, Zhou Z, Yang Y, Yin C, Chai GW. Effect of nickel sulfate on the concentrations of T3, T4 and TSH in serum of rat. *Wei Sheng Yan Jiu*, 1997; 26: 53-55.
17. Al-Mogairen SM, Al-Arfaj AS, Meo SA, Adam M, Al-Hammad A, Gad El Rab MO. Induction of autoimmunity in Brown Norway rats by oral and parenteral administration of sodium silicate. *Lupus* 2009; 18: 413-417.
18. Miller H, Zhang J, Kuolee R, Patel GB, Chen W. Intestinal M cells: the fallible sentinels? *World J Gastroenterol* 2007; 13: 1477-1486.