

Hypothyroid Graves' Ophthalmopathy: Report of Two Cases

Hipotiroid Graves Oftalmopatisi: İki Olgu Sunumu

Barış Akıncı, Tevfik Demir, Abdurrahman Çömlekçi

Division of Endocrinology and Metabolism, Department of Internal Medicine, Dokuz Eylül University Medical School, Izmir, Turkey

Abstract

Graves' disease is an autoimmune disorder of the thyroid gland. Ophthalmopathy is the most common peripheral manifestation of Graves' disease. It is a very rare condition that a Graves' patient presents with spontaneous hypothyroidism. Graves' ophthalmopathy in a hypothyroid subject without a history of treatment for hyperthyroidism is called hypothyroid Graves' disease. Here we describe two cases of hypothyroid Graves' disease presenting with overt hypothyroidism although they were not treated for hyperthyroidism previously. *Turk Jem 2007; 11: 26-8*

Key words: Graves' disease, hypothyroidism, ophthalmopathy

Özet

Graves hastalığı tiroid bezinin otoimmün bir hastalığıdır. Oftalmopati Graves hastalığının en sık görülen periferik manifestasyonudur. Graves hastalığında spontan hipotiroidi ile prezentasyon çok nadir bir durumdur. Hipertiroidi nedeniyle tedavi öyküsü olmayan hipotiroid bir bireyde Graves oftalmopatisi saptanması hipotiroid Graves hastalığı olarak adlandırılmaktadır. Bu yazıda daha önce hipertiroidi nedeniyle tedavi almamış olan ve klinik hipotiroidi ile başvuran iki hipotiroid Graves hastalığı olgusu sunulmuştur. *Turk Jem 2007; 11: 26-8*

Anahtar kelimeler: Graves hastalığı, hipotiroidi, oftalmopati

Introduction

Graves' disease is the most common cause of hyperthyroidism. Exophthalmos, pretibial myxedema, and acropachy are characteristic clinical findings of the disease. Ophthalmopathy occurs in 30% of Graves' disease cases (1). Hypothyroidism during the course of Graves' disease occurs commonly due to radioiodine therapy or thyroidectomy. It may also develop after anti-thyroid drug treatment. Presenting with spontaneous hypothyroidism is a very rare condition for patients with Graves' disease (2). Graves' ophthalmopathy develops in hypothyroid subjects without a history of treatment for hyperthyroidism is called hypothyroid Graves' disease (3). Here we report two cases of hypothyroid Graves' disease. The patients applied with symptoms of overt hypothyroidism although they were not treated for hyperthyroidism previously.

Case Reports

Case 1

A 75 year old woman was admitted to our hospital with complaint of pretibial edema. She gained five kg for the last one

year. She also noticed general malaise, feeling cold, hoarse voice and constipation. On physical examination, her skin was dry, she had propitosis and there was pretibial edema, particularly on the right lower extremity. Laboratory data revealed the presence of overt hypothyroidism with a thyrotropin (TSH) level of 94.1 µIU/ml (normal: 0.4-5), free 3,5,3'-triiodothyronine (FT3) of 1.76 pg/dl (normal: 1.8-4.2) and free thyroxine (FT4) of 0.54 ng/dl (normal: 0.8-1.9). Thyroid receptor antibody (TRAb) was 147 U/L (normal range: 0-9 U/L), anti thyroid peroxidase antibody (ATPO) titre was > 3000 IU/ml (normal range: 0-50 IU/ml). Anti thyroglobulin antibody (ATG) was negative. Ultrasonography of the thyroid showed hypoechoic thyroid gland. Right lobe was 18x16x35 mm and left lobe was 12x15x29 mm in size. Exophthalmos was documented with Hertel's exophthalmometer and magnetic resonance imaging (figure 1). Clinical activity score (CAS) was 0 and a NOSPECS of class 1 was found. Histopathologic examination of skin biopsy revealed the accumulation of mucopolysaccharides particularly in the reticular dermis when stained with Alcian blue. She was treated with levothyroxine replacement. Although there was regression of pretibial myxedema, exophthalmos remained stable after achieving euthyroidism by levothyroxine.

Case 2

A 48 years old male patient applied to the ophthalmologist with the complaint of asymmetrical proptosis. He had also per orbital edema. He gained four kg over the past one year. The patient had complaints of general malaise and feeling cold for six months. On physical examination; his eyes were red and watery. The covering of the eye is inflamed and swollen. Hertel's exophthalmometer confirmed the right proptosis (CAS: 6 and NOSPECS: 2a3a4b). Thyroid was soft, grade 1A palpable. Magnetic resonance imaging showed extraocular muscle enlargement in consistent with thyroid-associated

ophthalmopathy (figure 2). Thyroid function test revealed a TSH level of 64.21 μ U/ml (normal: 0.4-5), FT3 of 2.38 pg/dl (normal: 1.8-4.2) and FT4 of 0.41 ng/dl (normal: 0.8-1.9). TRAb was 33 U/L (normal range: 0-9 U/L), ATPO titre was > 3000 IU/ml (normal range 0-50 IU/ml), and ATG titre was >1000 IU/ml (normal range 0-50 IU/ml). Ultrasonography of the thyroid revealed hypoechoic thyroid gland. Right lobe was 18x24x42 mm and left lobe was 17x24x49 mm in size. Levothyroxine replacement was initiated. Intravenous methylprednisolone pulse therapy was given. The cumulative steroid dose was 8 g. Clinical findings of Graves' ophthalmopathy improved after steroid pulse therapy.

Discussion

Graves' disease, an autoimmune disease of the thyroid gland, follows the production of IgG auto antibodies directed primarily against the thyrotropin (TSH) receptor (1). While the pathogenesis of Graves' ophthalmopathy is still uncertain, an inflammatory reaction, associated with antithyroid antibody action, is well established in orbital tissues in Graves' ophthalmopathy. The TSH-receptor represents an antigen shared between the thyroid and the orbital tissues in Graves' disease, thus being a candidate link for extrathyroidal manifestation of disease (2). Binding sites for both the TSH and the TSH receptor antibody have been demonstrated on the orbital cells. TSH receptor variants have been also detected in orbital tissue (4). Expression of the TSH receptor have been found to be increased in orbital preadipocytes (5). Other possible mechanisms of Graves' ophthalmopathy are T cells reacting with TSH receptor and various cytokines that stimulate fibroblast proliferation (2, 6).

Although TRAb's are generally regarded as mediators of thyroid stimulation in Graves' disease, some TRAb's are blocking type antibodies (2). The possibility that TSH blocking antibodies are a significant cause of hypothyroidism in hypothyroid Graves' disease is unclear. One third of patients with Graves' disease who developed hypothyroidism after antithyroid drugs had a blocking type TRAb (7). However, Kasagi et al. (8) examined five cases of hypothyroid Graves' disease and detected stimulating, not blocking type, TRAb in all patients. This result suggest that hypothyroidism in these cases is not related with the presence of blocking type antibodies. They considered that hypothyroidism in these cases may be associated with high antibody titres against Tg and M or destructive changes in the thyroid, which are demonstrated by ultrasound and histological examination, due to the concomitant presence of Hashimoto's thyroiditis. Thyroid ophthalmopathy may less frequently occur also in patients with hypothyroid Hashimoto's thyroiditis (9). Graves' disease and Hashimoto's thyroiditis are often viewed as discrete clinical entities; although there is some evidence that these diseases may represent a spectrum of autoimmune thyroid dysfunction (10). As we report, hypothyroid Graves' patients may have high antibody titres against thyroid peroxidase and hypoechoic thyroid gland on ultrasonography. Thyroid failure in hypothyroid Graves' disease may occur because of thyroid destruction due to concomitant Hashimoto's disease.

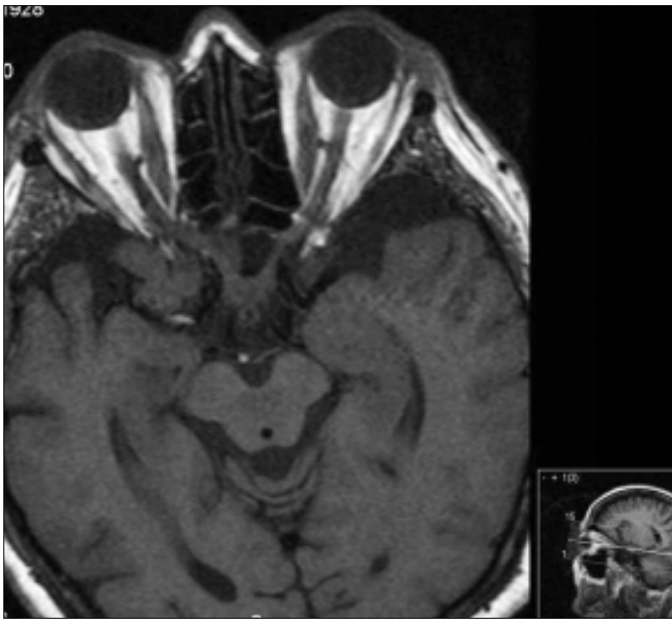


Figure 1. Magnetic resonance imaging of case-1 revealed Graves' ophthalmopathy

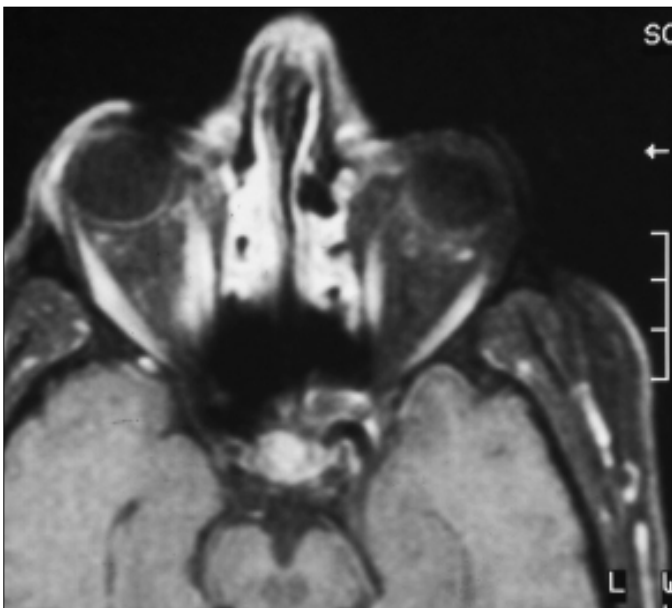


Figure 2. Magnetic resonance imaging of case-2 showed extraocular muscle enlargement consistent with Graves' ophthalmopathy

References

1. McIver B, Morris JC. The pathogenesis of Graves' disease. *Endocrinol Metab Clin North Am* 1998; 27: 73-89.
2. Bartalena L, Wiersinga WM, Pinchera A. Graves' ophthalmopathy: state of the art and perspectives. *J Endocrinol Invest* 2004; 27: 295-301.
3. Christy JH, Morse RS. Hypothyroid Graves' disease. *Am J Med* 1977; 62: 291-6.
4. Paschke R, Metcalfe A, Alcalde L, et al. Presence of nonfunctional thyrotropin receptor variant transcripts in retroocular and other tissues. *J Clin Endocrinol Metab* 1994; 79: 1234-8.
5. Valyasevi RW, Erickson DZ, Harteneck DA, et al. Differentiation of human orbital preadipocyte fibroblasts induces expression of functional thyrotropin receptor. *J Clin Endocrinol Metab* 1999; 84: 2557-62.
6. Stadlmayr W, Spitzweg C, Bichlmair AM, Heufelder AE. TSH receptor transcripts and TSH receptor-like immunoreactivity in orbital and pretibial fibroblasts of patients with Graves' ophthalmopathy and pretibial myxedema. *Thyroid* 1997; 7: 3-12.
7. Tamai H, Kasagi K, Takaichi Y, et al. Development of spontaneous hypothyroidism in patients with Graves' disease treated with antithyroidal drugs: clinical, immunological, and histological findings in 26 patients. *J Clin Endocrinol Metab* 1989; 69: 49-53.
8. Kasagi K, Hidaka A, Nakamura H, et al. Thyrotropin receptor antibodies in hypothyroid Graves' disease. *J Clin Endocrinol Metab* 1993; 76: 504-8.
9. Burch HB, Wartofsky L. Graves' ophthalmopathy: current concepts regarding pathogenesis and management. *Endocr Rev* 1993; 14: 747-93.
10. Dayan CM, Daniels GH. Chronic autoimmune thyroiditis. *N Engl J Med* 1996; 335: 99-107.