

Retrotracheal Parathyroid Adenoma Presenting with Mandibular Giant Cell Granuloma

Mandibüler Dev Hücreli Granülom ile Tanı Alan Retrotrakeal Paratiroid Adenomumu

Mehtap Çakır, Saif Gönen, Gülsün Öz*

Selçuk University, School of Medicine, Division of Endocrinology and Metabolism, Konya, Turkey
*Selçuk University, Faculty of Dentistry, Department of Oral and Maxillofacial Surgery, Konya, Turkey

Abstract

For the past two decades, primary hyperparathyroidism generally has been diagnosed at an asymptomatic stage because of routine biochemical screening. Bone involvement and dental changes are late manifestations of primary hyperparathyroidism, and brown tumors are seen rarely. We present here a case who admitted to the dentistry clinic with left mandibular swelling diagnosed on pathologic examination as giant cell granuloma. Further investigation revealed brown tumors localized to the mandible and was secondary to primary hyperparathyroidism. Primary hyperparathyroidism can present in a variety of ways and should be included in the differential diagnosis of cystic bone lesions, although at present, these lesions are seen rarely. *Turk Jem 2009; 13: 8-10*

Key words: Primary hyperparathyroidism, parathyroid adenoma, brown tumor, mandible

Özet

Son yıllarda biyokimyasal tetkiklerin rutin olarak yapılması nedeniyle primer hiperparatiroidi zaman zaman asemptomatik safhada saptanabilmektedir. Kemik değişiklikleri ve diş problemleri primer hiperparatiroidinin geç bulgularıdır ve kahverengi kemik tümörleri artık çok sık görülmemektedir. Bu yazıda sol mandibüler bölgede şişlik şikayeti ile diş kliniğine başvuran, patolojik olarak dev hücreli granülom tanısı alan ve ayırıcı tanı tetkikleri sonrası primer hiperparatiroidi tanısı konan bir hasta sunulmuştur. *Turk Jem 2009; 13: 8-10*

Anahtar kelimeler: Primer hiperparatiroidi, paratiroid adenomu, kahverengi tümör, mandibüla

Introduction

For the past two decades, routine biochemical screening has resulted in earlier diagnosis of primary hyperparathyroidism (PHPT) at an asymptomatic stage. It is generally believed that skeletal pathology is a manifestation of advanced PHPT; however, brown tumors, which usually occur in the ribs, clavicle and pelvic girdle, can be the first manifestation of PHPT. Brown tumors of the maxillofacial region may also be seen in PHPT, albeit rarely.

When brown tumors occur in the head and neck, they may involve the maxilla, orbital bones, mandible, and palatal region. Patients with such tumors usually present to dentistry clinics with expansile masses. We present here a patient who was referred to our endocrinology clinic from the Faculty of Dentistry

with swelling localized to the left mandibular region, and hypercalcemia. The patient was diagnosed with brown tumors secondary to PHPT.

Case Report

A 35-year-old man was referred to the Faculty of Dentistry, Department of Oral and Maxillofacial Surgery, with a complaint of swelling and pain localized to the left mandibular molar area. The patient had his mandibular left second molar tooth extracted six months previously. Two months after extraction he noticed facial deformity and swelling at the left side of the mandibular alveolar crest, and was referred to the dentistry clinic.

Address for Correspondence: Mehtap Çakır, MD, Selçuk University, Meram School of Medicine, Division of Endocrinology and Metabolism, Konya, Turkey
E-mail: cakirmehtap@yahoo.com **Received:** 16.12.2008 **Accepted:** 18.05.2009

Turkish Journal of Endocrinology and Metabolism, published by Galenos Publishing. All rights reserved.

Oral examination showed a mass extending from left mandibular molar area to the right mandibular first and second central incisors. The lesion caused expansion buccally and lingually, and central incisors were mobile (Fig. 1). Medical history revealed no dental trauma or unusual infection.

Panoramic radiograph of the jaw revealed a radiolucent lesion extending from the left mandibular molar area to the right anterior mandible (Fig. 2). The roots of the central incisors were widely displaced, but there was no evidence of root resorption. Magnetic resonance imaging of the head revealed two mass lesions, one 2.5x2 cm on the left mandibular corpus, and the other 2x1.5 cm on the mental region of the mandible, which showed homogenous contrast uptake, and caused significant expansion and bone destruction.

An incisional biopsy was performed under local anesthesia. The specimen included the incisors, molars, and a margin of uninvolved tissue. Histologically, multinuclear giant cells and stromal cells typical for giant cell granuloma were seen. According to these features, the histopathological diagnosis was "giant cell granuloma". Laboratory examination revealed elevated serum calcium, and the patient was referred to endocrinology outpatient clinic for further investigation of hypercalcemia with a preliminary diagnosis of brown tumors secondary to hyperparathyroidism.

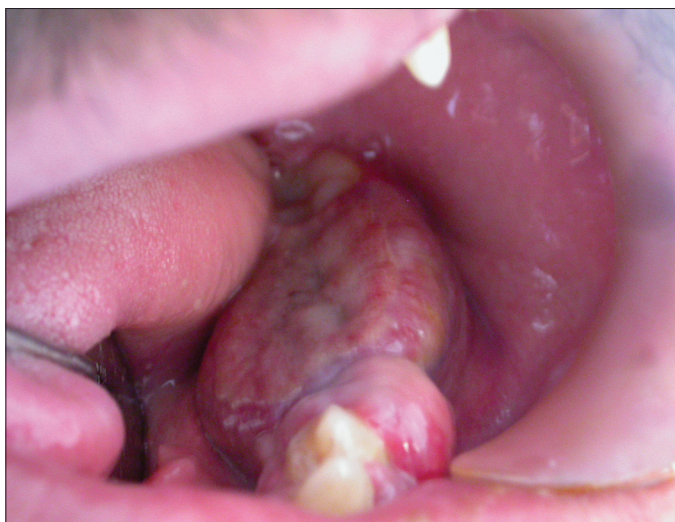

Figure 1. Photograph of the oral cavity showing swelling of left mandibular region

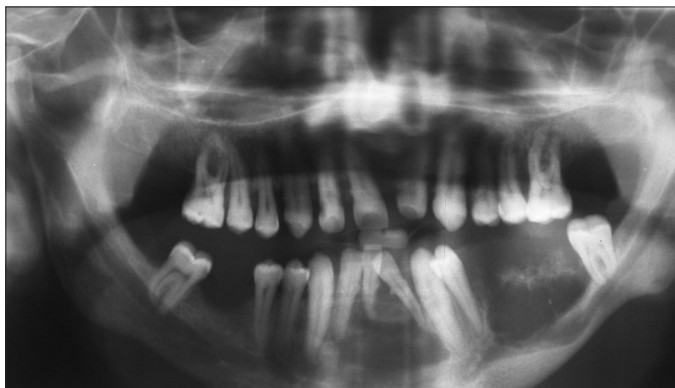

Figure 2. Panoramic radiograph of the jaw showing a radiolucent lesion extending from the left mandibular molar area to the right anterior mandible

On admission, the patient complaints of nausea and vomiting. Physical examination was unremarkable except for swelling noted on his left mandibular region. Complete blood count, and renal and liver function tests were within normal limits. Serum calcium and phosphorus levels were 3.4 mmol/L and 0.6 (0.7-1.5) mmol/L, respectively. Twenty-four hour urinary calcium excretion was 348 (12.5-75) mmol/day. Serum intact parathormone level was high; 487.3 (11-79) ng/L.

Renal ultrasonography revealed nephrocalcinosis in both kidneys. No other bone lesion was detected on bone x-rays or on Tc-99m MDP whole body bone scan. On Tc-99m MIBI scan, MIBI uptake was seen on left hemithyroidal region in late images, consistent with a parathyroid adenoma (Fig. 3). During surgery, a parathyroid adenoma could not be definitively identified. A mass lesion in the left hemithyroidal region, consistent with the area in which uptake was noted on Tc-99m MIBI scan, was removed with left thyroid lobectomy as small nodules were palpated in the left thyroid lobe.

Pathological examination of the surgical specimen revealed nodular goiter, thymic tissue, and a normal appearing parathyroid gland. The patient's high calcium levels persisted after the operation, and PTH was 656 (16-87) ng/L. A second Tc-99m MIBI scan was performed, demonstrating uptake in the same region as seen in the previous Tc-99m MIBI scan. The second surgical intervention was successful, and a retrotracheal parathyroid adenoma was removed. The pathological diagnosis was parathyroid adenoma. Postoperative calcium levels decreased to 2.15 (2.2-2.6) mmol/L, phosphorus was 1.4 (0.7-1.5) mmol/L and PTH level was 98.7 (16-87) ng/L. With a diagnosis of hungry bone syndrome, oral calcium and vitamin D supplementations were started.

Three months following surgery, serum calcium, phosphorus, PTH, 24 hour urinary calcium, and phosphorus levels returned to normal. The mass lesion on the patient's mandible partially regressed; the patient continues to be followed for any signs of recurrence.

Discussion

Primary hyperparathyroidism is the most common cause of hypercalcemia in the outpatient setting (1). In a recent review by Ruda et al., which included 20.225 cases of primary hyperparathyroidism, solitary adenomas (SA), multiple gland hyperplasia disease (MGHD), double adenomas (DA), and parathyroid carcinomas (CAR) occurred in 88.90%, 5.74%, 4.14%, and

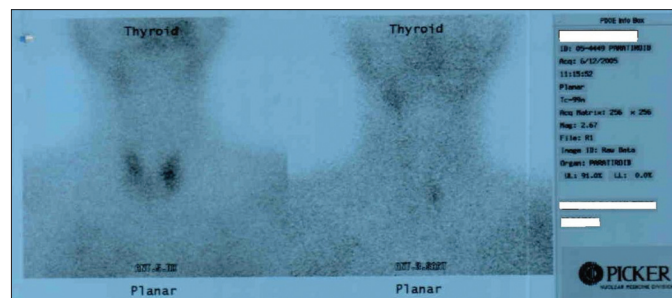


Figure 3. Tc-99m MIBI scan of the patient prior to surgery showing MIBI uptake in the left thyroidal region

0.74% of cases, respectively (2). Primary hyperparathyroidism can be sporadic, familial, or be a component of multiple endocrine neoplasia (MEN) I and IIa.

Clinical features of primary hyperparathyroidism have changed dramatically over the years owing to improved diagnostic laboratory methods. Many cases are detected at an early stage before having symptoms or signs of the disease. These patients are diagnosed as having asymptomatic (3). Asymptomatic hyperparathyroidism accounts for 75-80% of cases (4). Consistent with this data, the frequency of specific radiological bone manifestations of primary hyperparathyroidism has fallen from 23% to less than 2% (5). As a result, skeletal radiographs are not routinely recommended.

Brown tumors are non-neoplastic lesions found only in the presence of hyperparathyroidism. They are osteoclastomas that are very similar both radiologically and histologically to giant cell granulomas, which are lesions that occur almost exclusively in the jaws. Differential diagnosis includes giant cell reparative granuloma, cherubism, true giant cell tumor, aneurysmal bone cyst, and solitary bone cyst (6). Central giant cell granulomas (arising from within the bone) are generally associated with hyperparathyroidism, whereas peripheral giant cell granulomas arising from or near the surface of the bone apparently are not associated with hyperparathyroidism (7); however it is advisable to test for hyperparathyroidism in the latter condition, if multiple lesions occur. There are case reports in the literature for unusual localizations of brown tumors including the palatal region, maxilla, orbit, and sellar region (8).

Successful parathyroidectomy can result in regression of brown tumors. In a follow-up study of subjects with osteitis fibrosa cystica, Agarwal et al. reported that brown tumors and fractures showed hyperdensities within three months and brown tumors regressed partially in nearly 22% of patients after six months. However, in some cases, brown tumors continued to grow even though patients had been normocalcemic for two to three months, and even two years after parathyroidectomy (9). In these instances, local curettage or enucleation

was recommended. For our patient, because it has been only three months since parathyroidectomy, treatment strategy for the brown tumors will be decided later.

In conclusion, although the current trend in the diagnosis of PHPT is the discovery asymptomatic disease, there are still cases presenting with advanced bone disease. Therefore, all giant cell lesions should be investigated to exclude hyperparathyroidism. Postoperative persistence of elevated PTH levels should be interpreted with serum calcium, phosphorus, and vitamin D levels for the differential diagnosis of unsuccessful surgery, hungry bone syndrome, and vitamin D deficiency.

References

1. Kearns AE, Thompson GB. Medical and surgical management of hyperparathyroidism. *Mayo Clin Proc* 2002; 77: 87-91.
2. Ruda JM, Hollenbeak CS, Stack BC Jr. A systematic review of the diagnosis and treatment of primary hyperparathyroidism from 1995 to 2003. *Otolaryngol Head Neck Surg* 2005; 132: 359-72.
3. Bilezikian JP, Khan AA, Potts JT Jr. on behalf of the Third International Workshop on the Management of Asymptomatic Primary Hyperparathyroidism. Guidelines for the Management of Asymptomatic Primary Hyperparathyroidism: Summary Statement from the Third International Workshop. *J Clin Endocrinol Metab* 2009;94:335-9.
4. Solimando DA. Overview of hypercalcemia of malignancy. *Am J Health Syst Pharm* 2001; 58(suppl 3): S4-7.
5. Bilezikian JP, Silverberg SJ. Clinical spectrum of primary hyperparathyroidism. *Rev Endocr Metab Disord* 2000; 1: 237-45.
6. Martínez-Gavidia EM, Bagán JV, Miliñ-Masanet MA, Lloria de Miguel E, Pérez-Vallés A. Highly aggressive brown tumor of the maxilla as first manifestation of primary hyperparathyroidism. *Int J Oral Maxillofac Surg* 2000; 29: 447-9.
7. Redman RS. Dental aspects of endocrinology. *Principles and Practice of Endocrinology and Metabolism* 3. edition (Ed. Becker KL). Philadelphia, PA, Lippincott Williams & Wilkins 2001, 1981-91.
8. Daniels JS. Primary hyperparathyroidism presenting as a palatal brown tumor. *Oral Surg Oral Med Oral Pathol Oral Radiol Endod* 2004; 98: 409-13.
9. Agarwal G, Mishra SK, Kar DK, Singh AK, Arya V, Gupta SK, Mithal A. Recovery pattern of patients with osteitis fibrosa cystica in primary hyperparathyroidism after successful parathyroidectomy. *Surgery* 2002; 132: 1075-83.